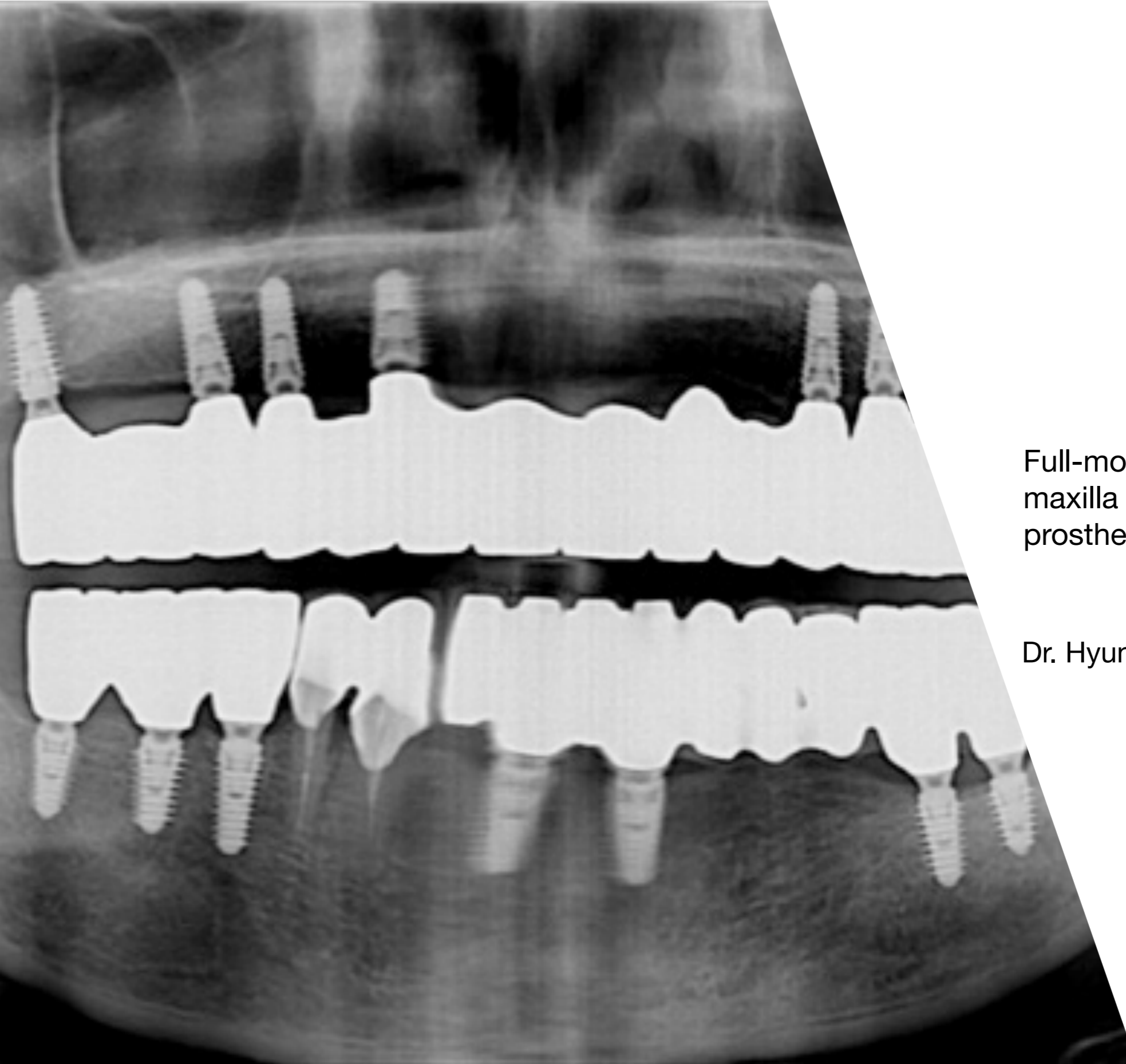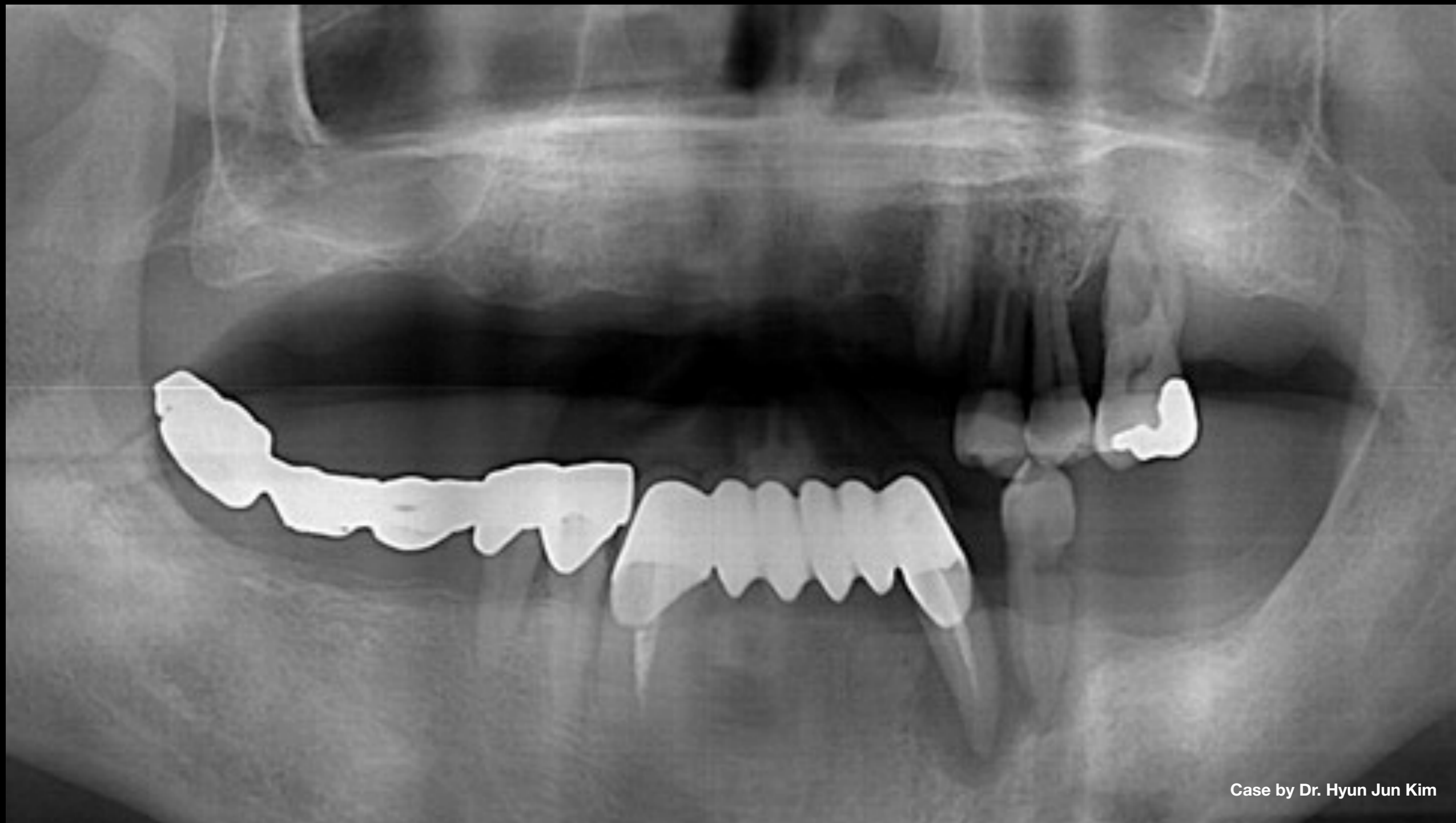


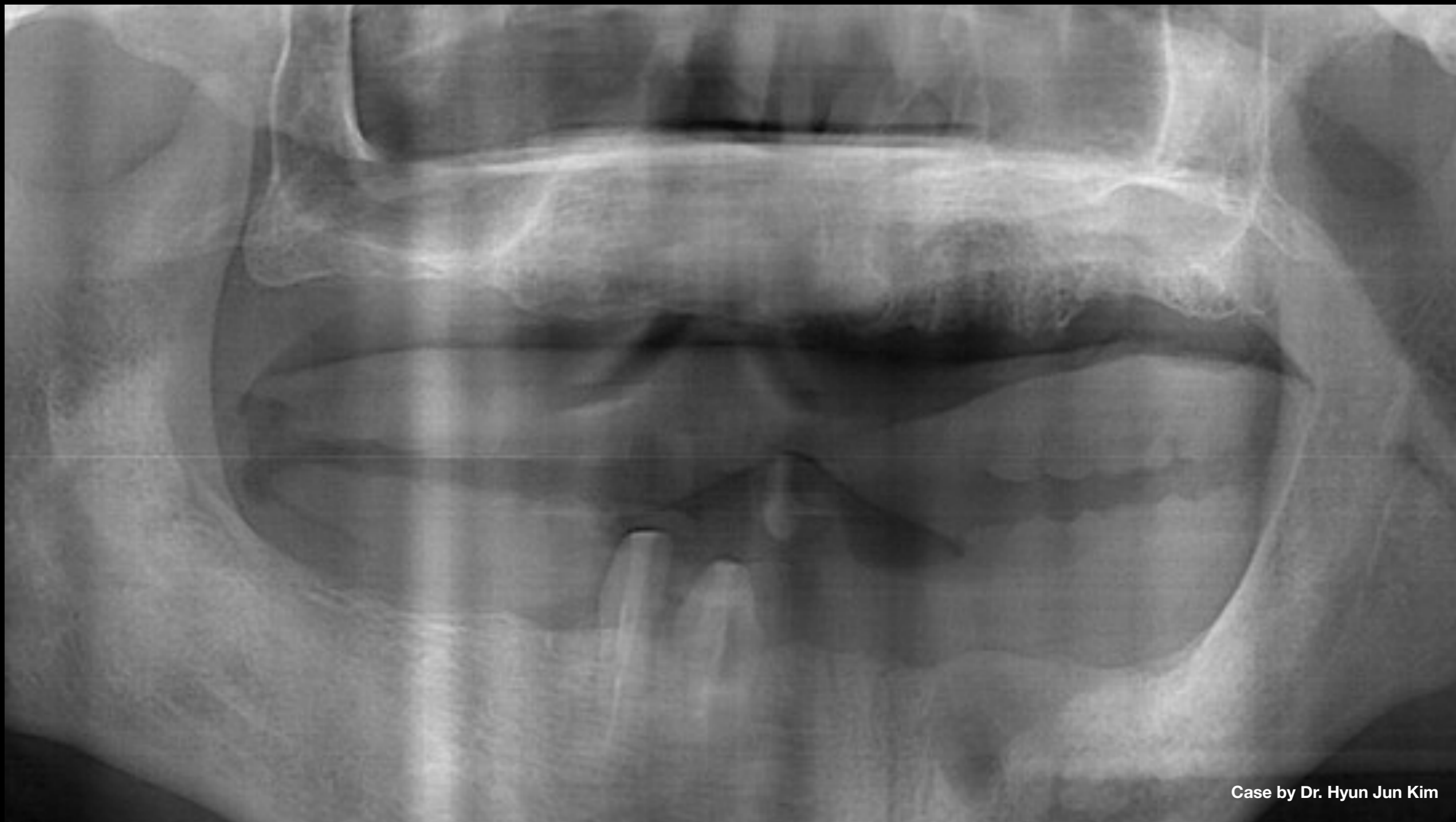Full-mouth implants for mandibular & maxilla - restored using mixed prostheses

Dr. Hyun Jun Kim



Case by Dr. Hyun Jun Kim

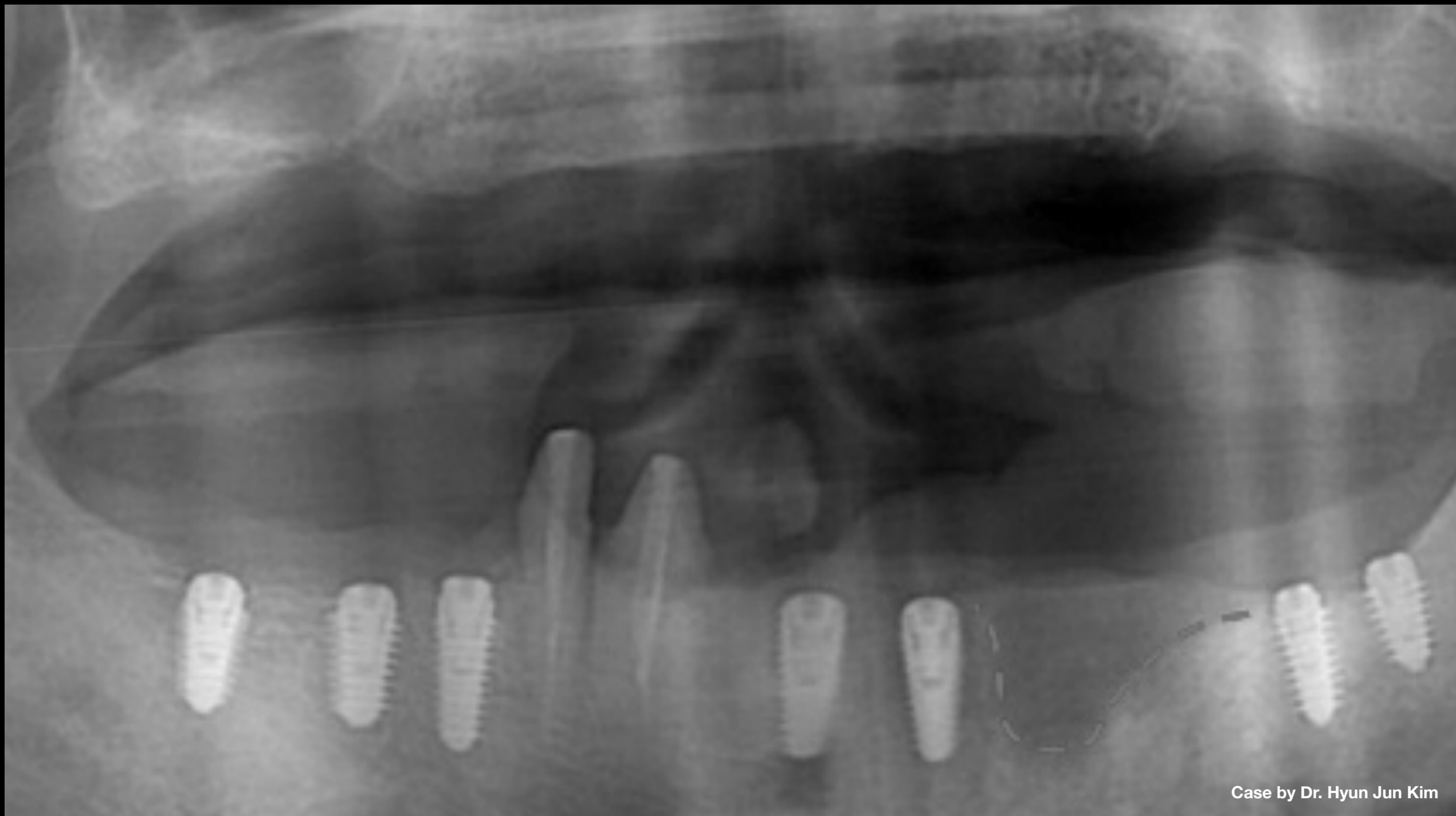
**Clinical Case:** Pre-op panoramic scan



Case by Dr. Hyun Jun Kim

**Clinical Case:** Extraction of all teeth except #43 & 44



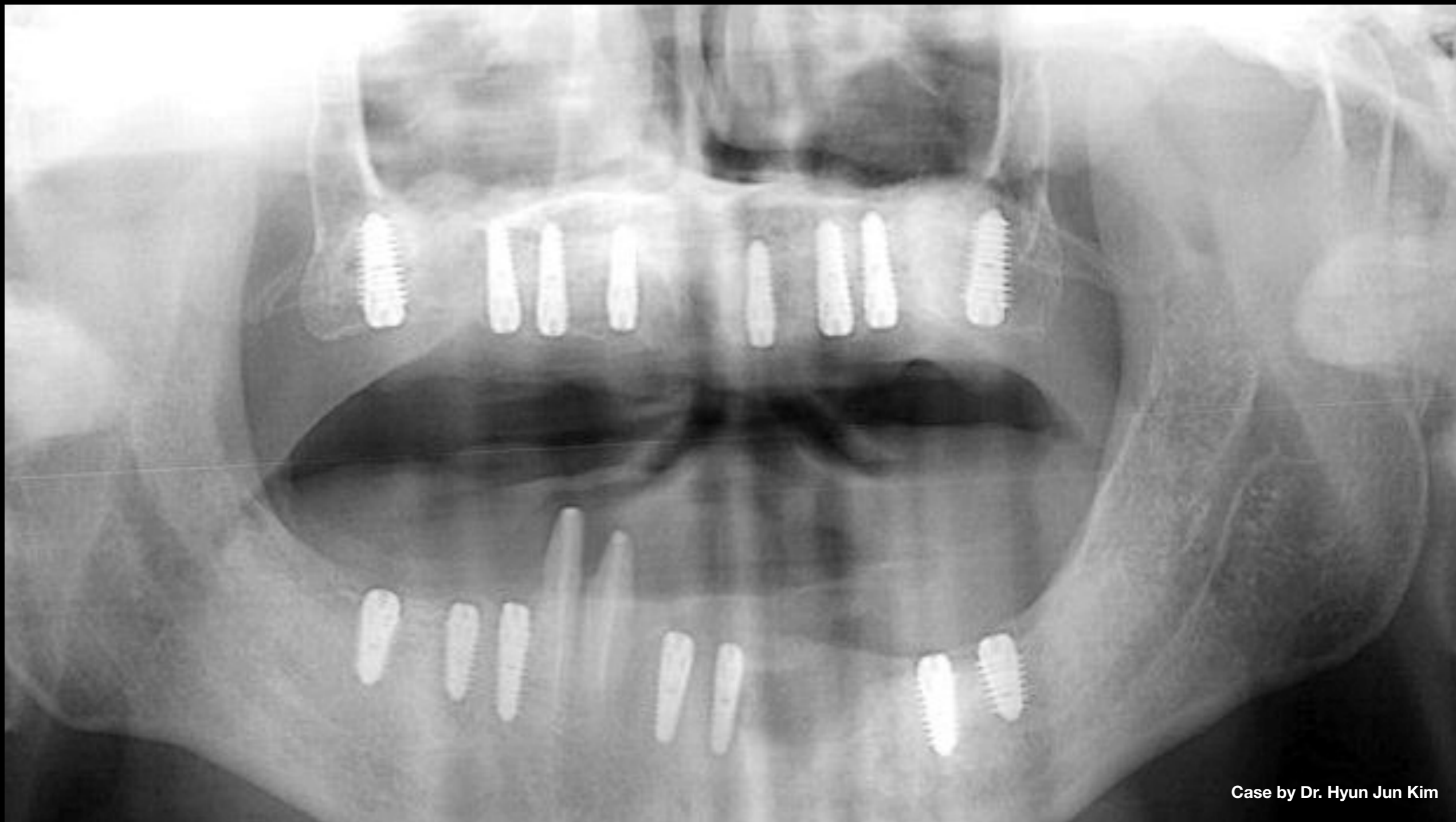

Case by Dr. Hyun Jun Kim

**Clinical Case:**

- Post-op panoramic scan (mandibular)
- Serious bone resorption was observed on upper labial side of red dotted line, so bone resorption area was avoided & implants placed in healthy bone

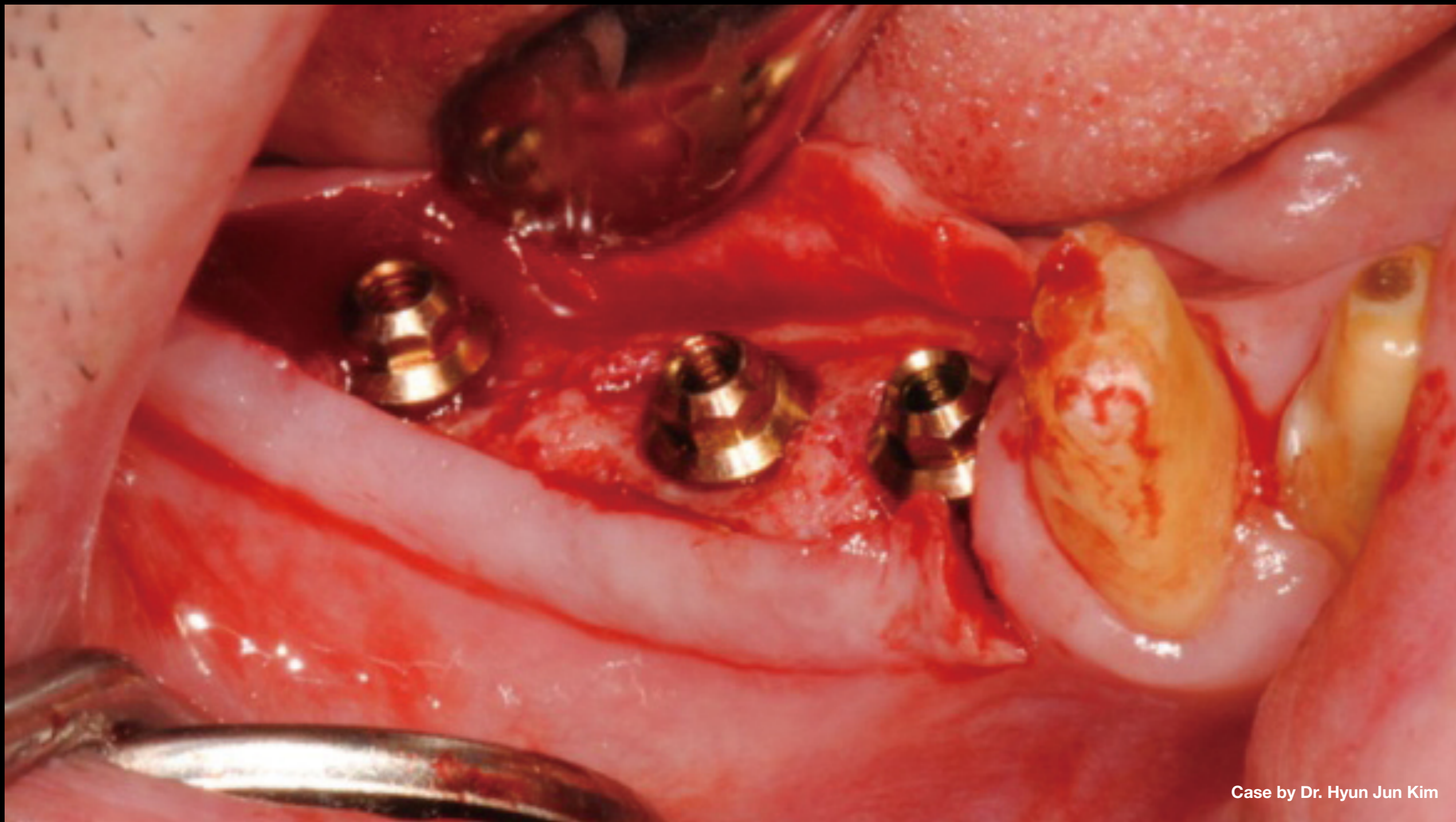




Case by Dr. Hyun Jun Kim

**Clinical Case:** Post-op panoramic scan (maxilla) showing placement of AnyRidge implants after bilateral sinus graft

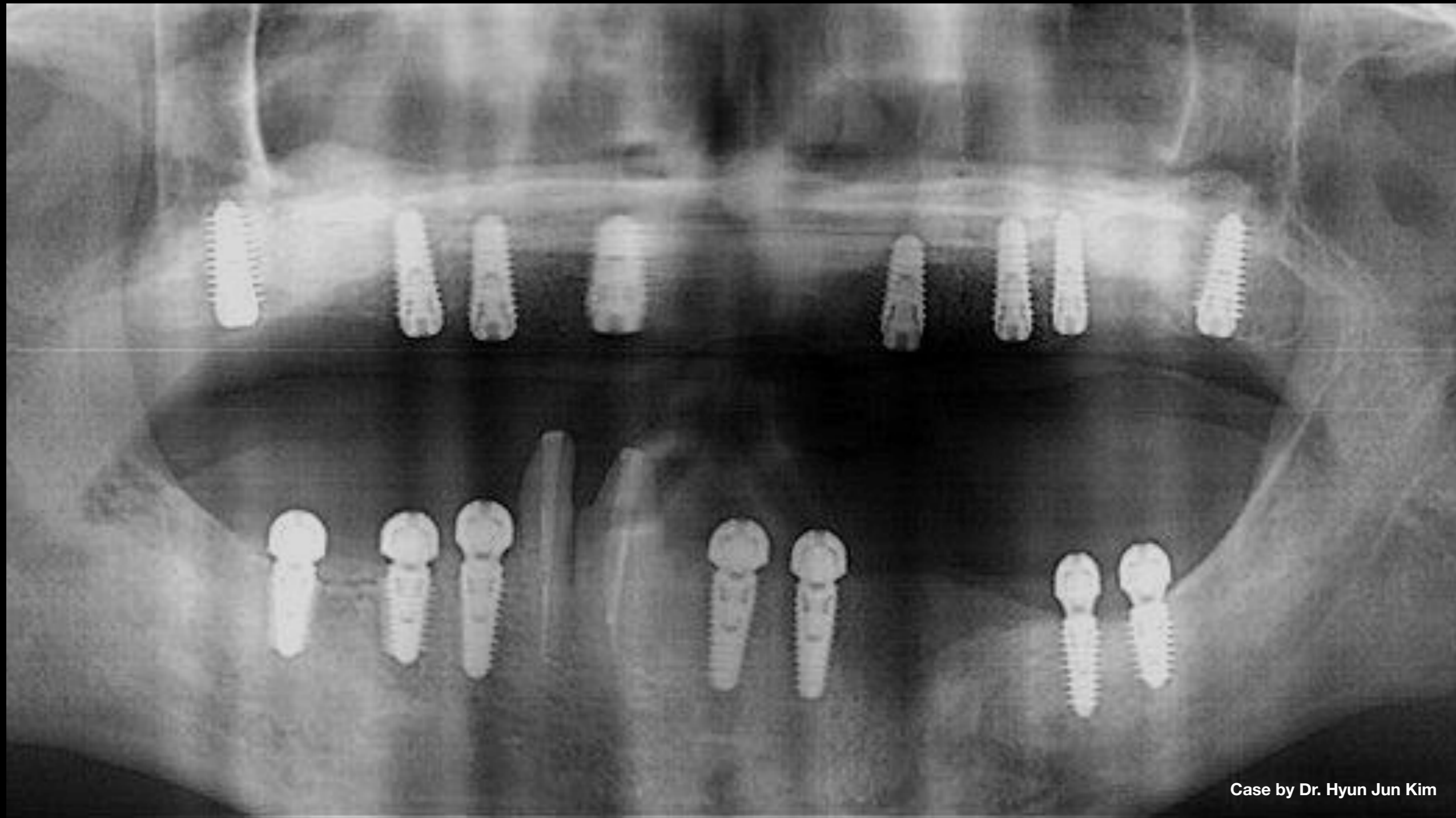




Case by Dr. Hyun Jun Kim

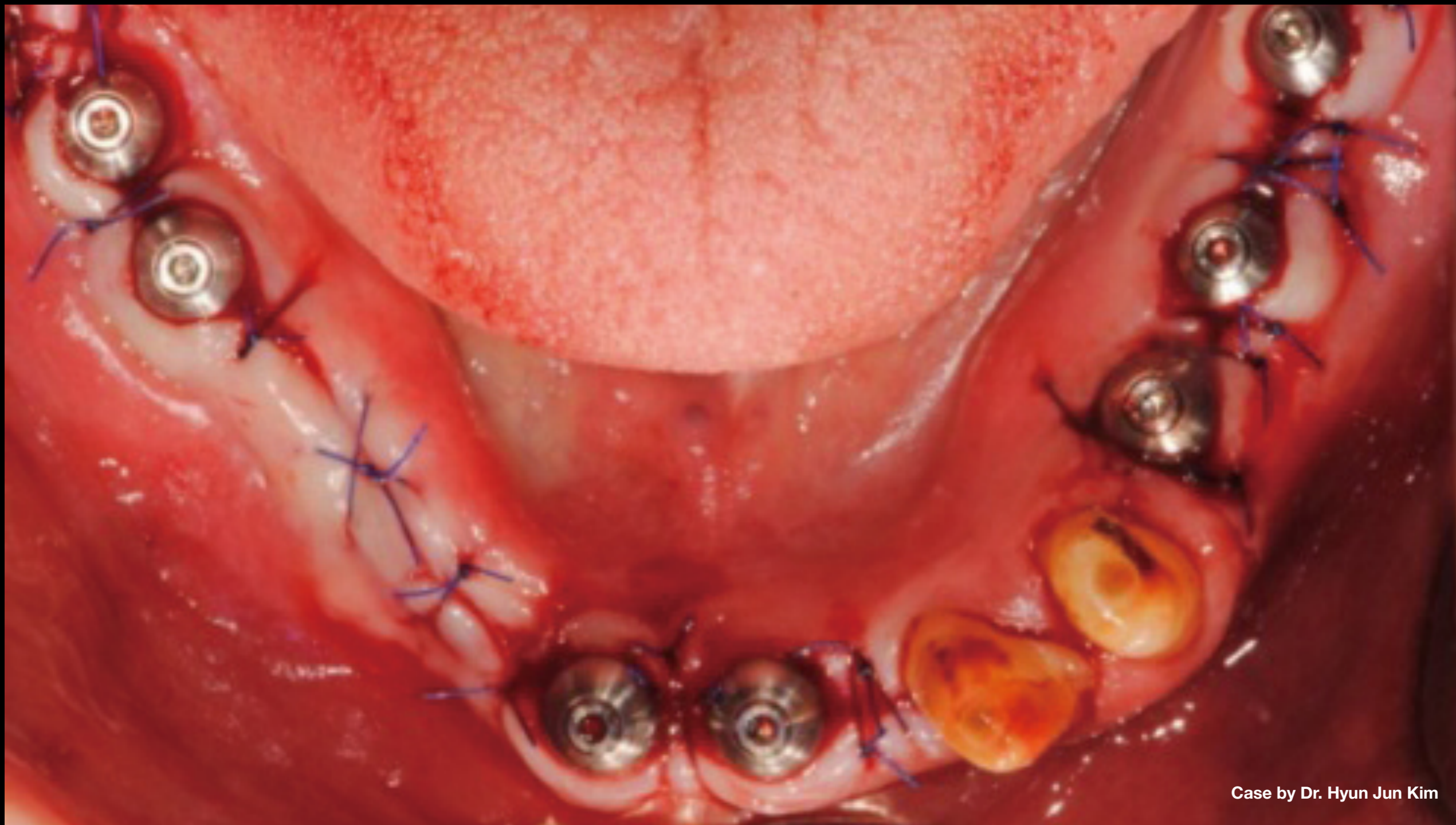
**Clinical Case:** 3 mths post 2nd op & connection with Octa abutment: 35N (mandibular)





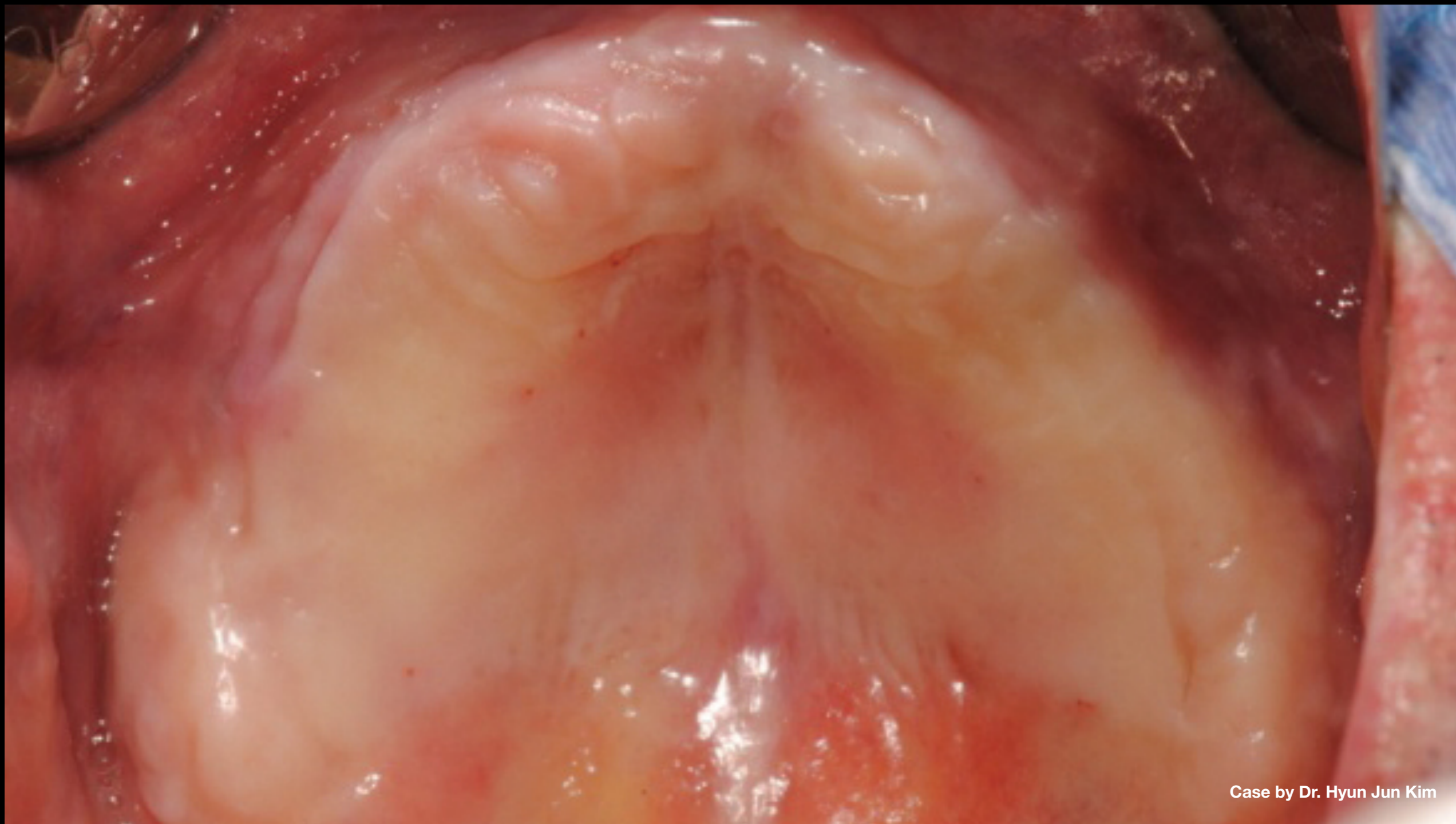
Case by Dr. Hyun Jun Kim

**Clinical Case:** Cuff height of Octa abutment selected according to gingiva thickness #36, 37 - 2mm #32, 41 - 1mm #46, 47- 1mm



Case by Dr. Hyun Jun Kim

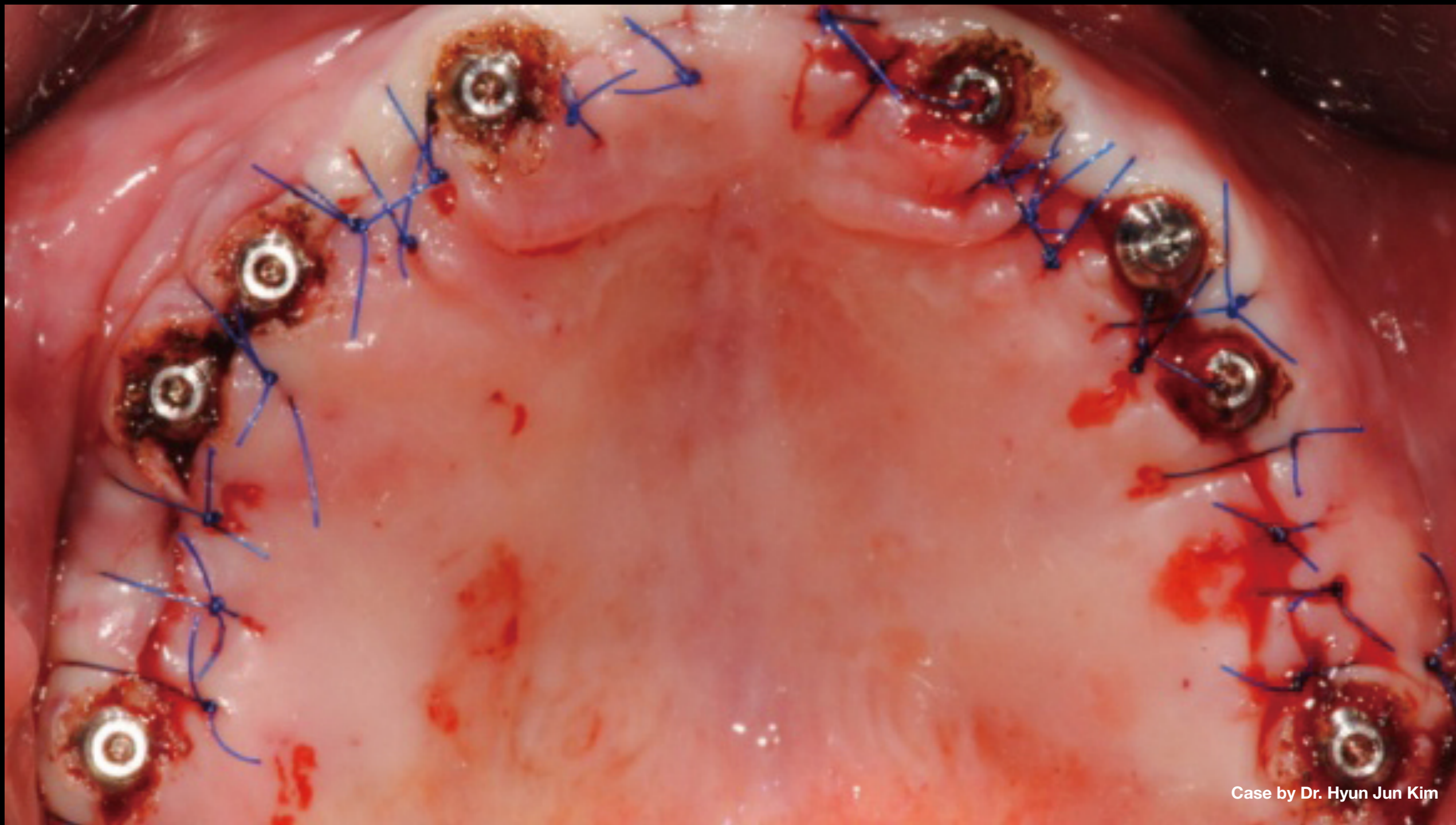
**Clinical Case:** Cuff height of Octa abutment selected according to gingiva thickness #36, 37 - 2mm #32, 41 - 1mm #46, 47- 1mm



Case by Dr. Hyun Jun Kim

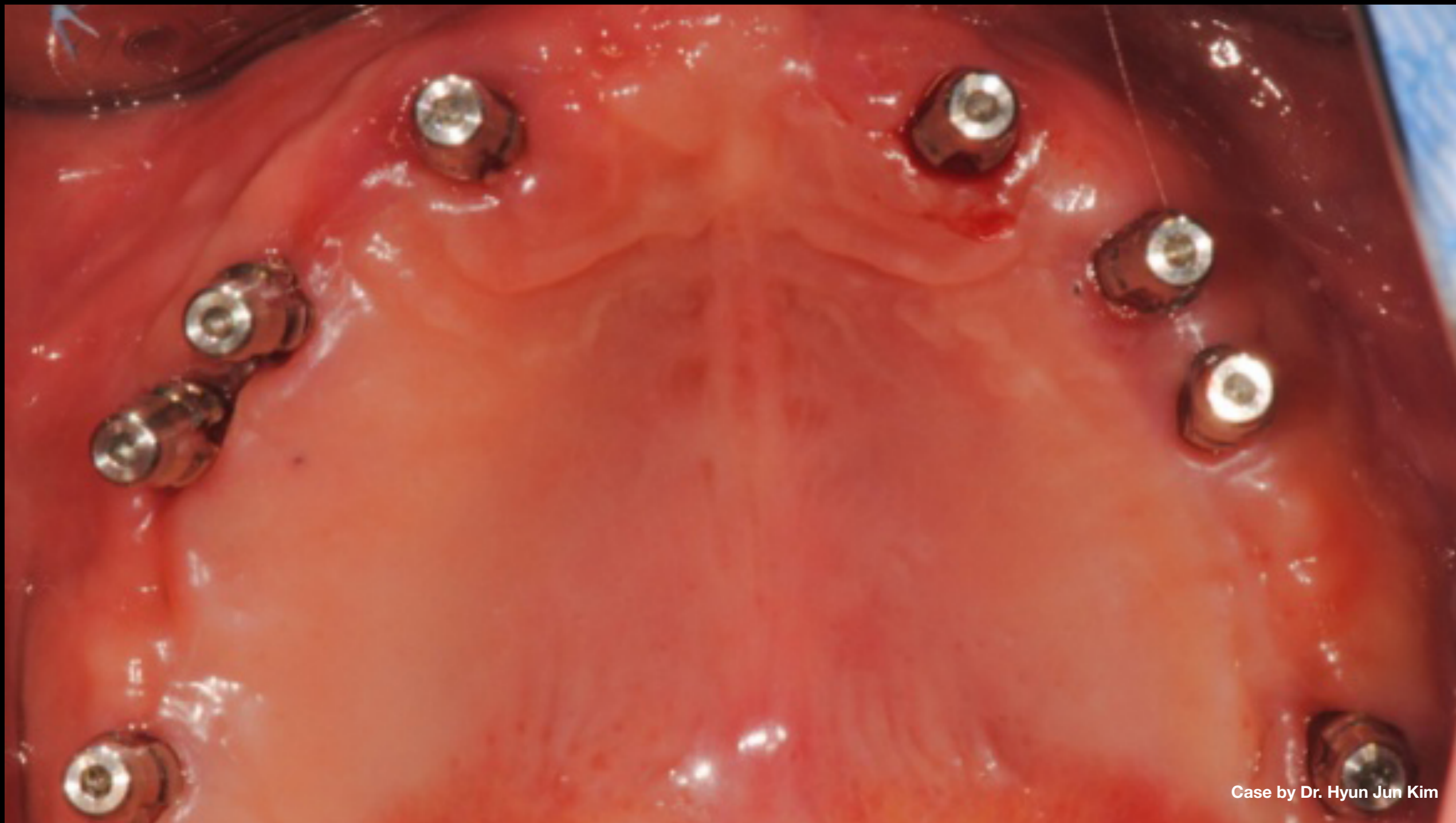**Clinical Case:**

- Pre 2nd op photo
- Patient used PR during healing period (4 mths) & cover screw was not exposed
- If using external-type fixture, screw can be exposed



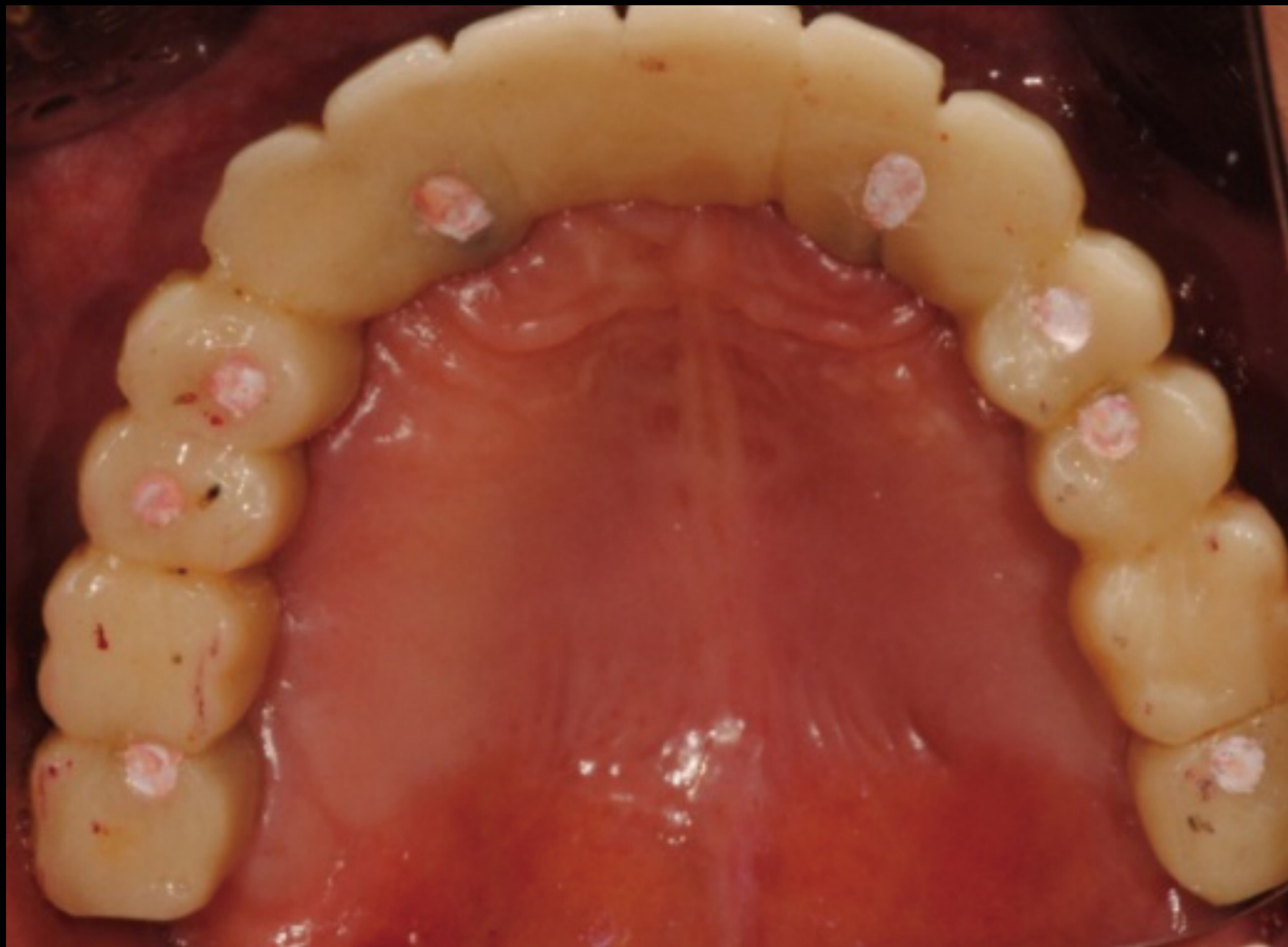
Case by Dr. Hyun Jun Kim

**Clinical Case:** Connection of Octa abutment & THA



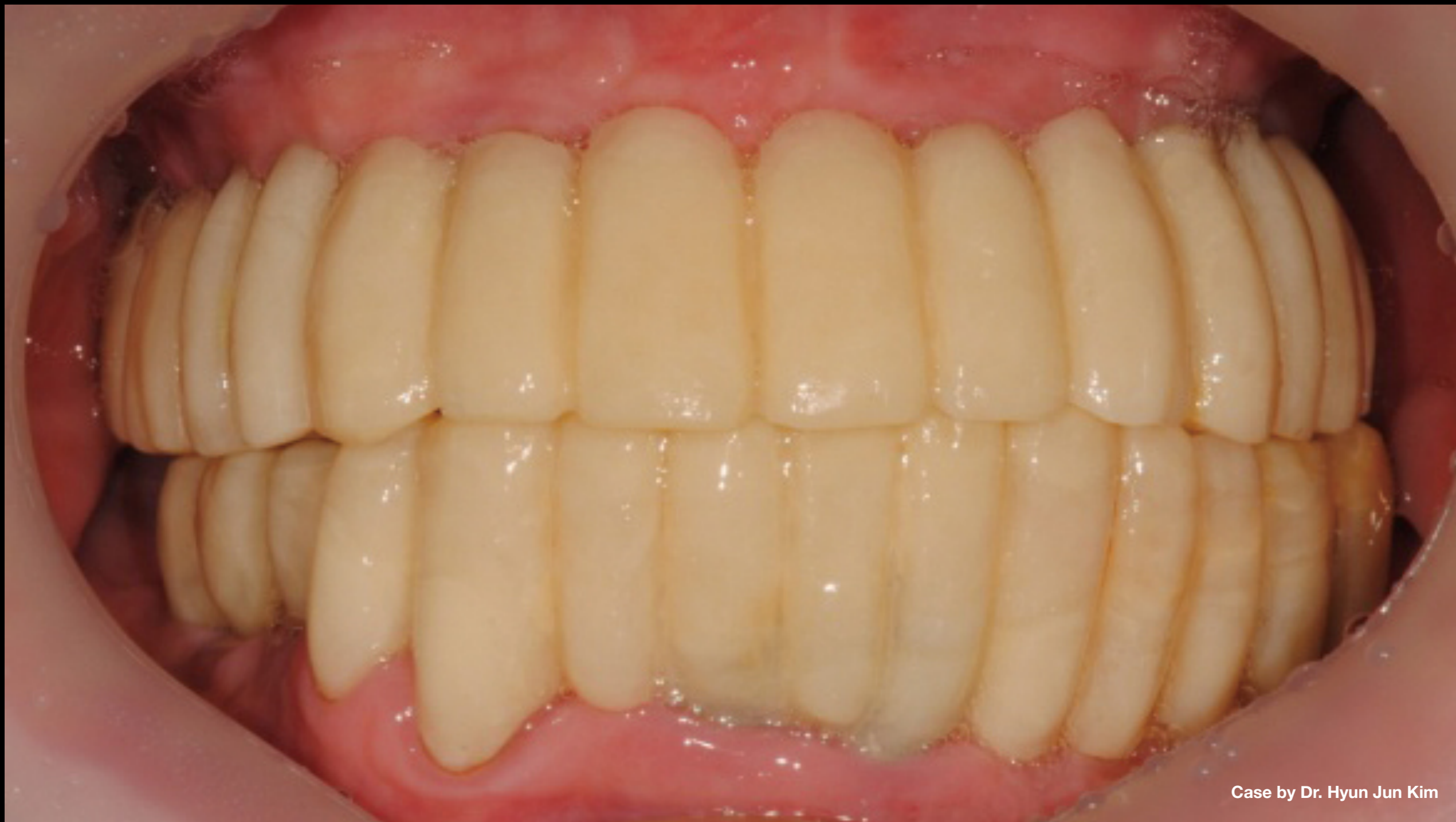Case by Dr. Hyun Jun Kim

**Clinical Case:** PR impression taken using transfer-type impression coping



Case by Dr. Hyun Jun Kim

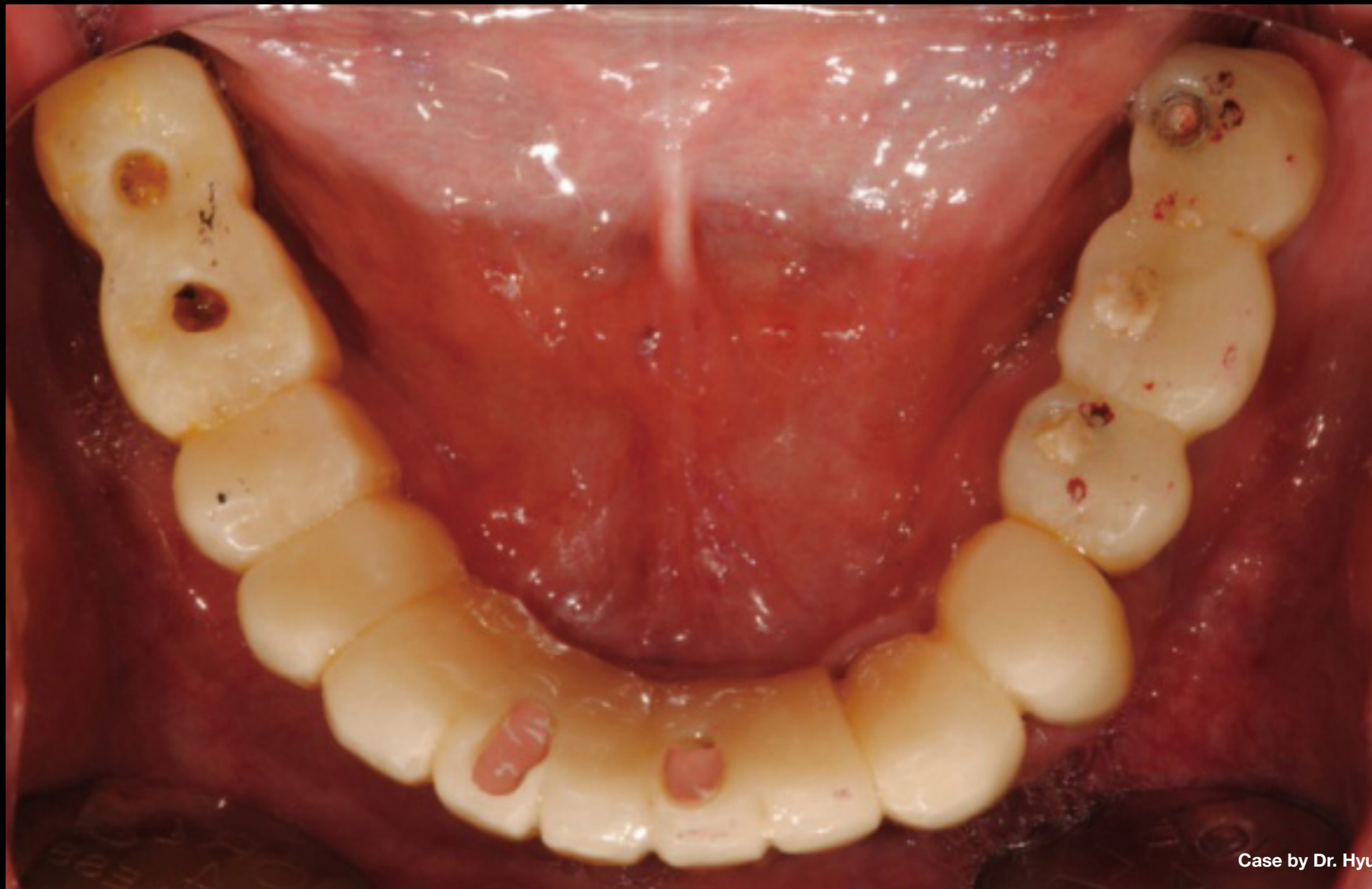
**Clinical Case:** Provisional delivery



Case by Dr. Hyun Jun Kim

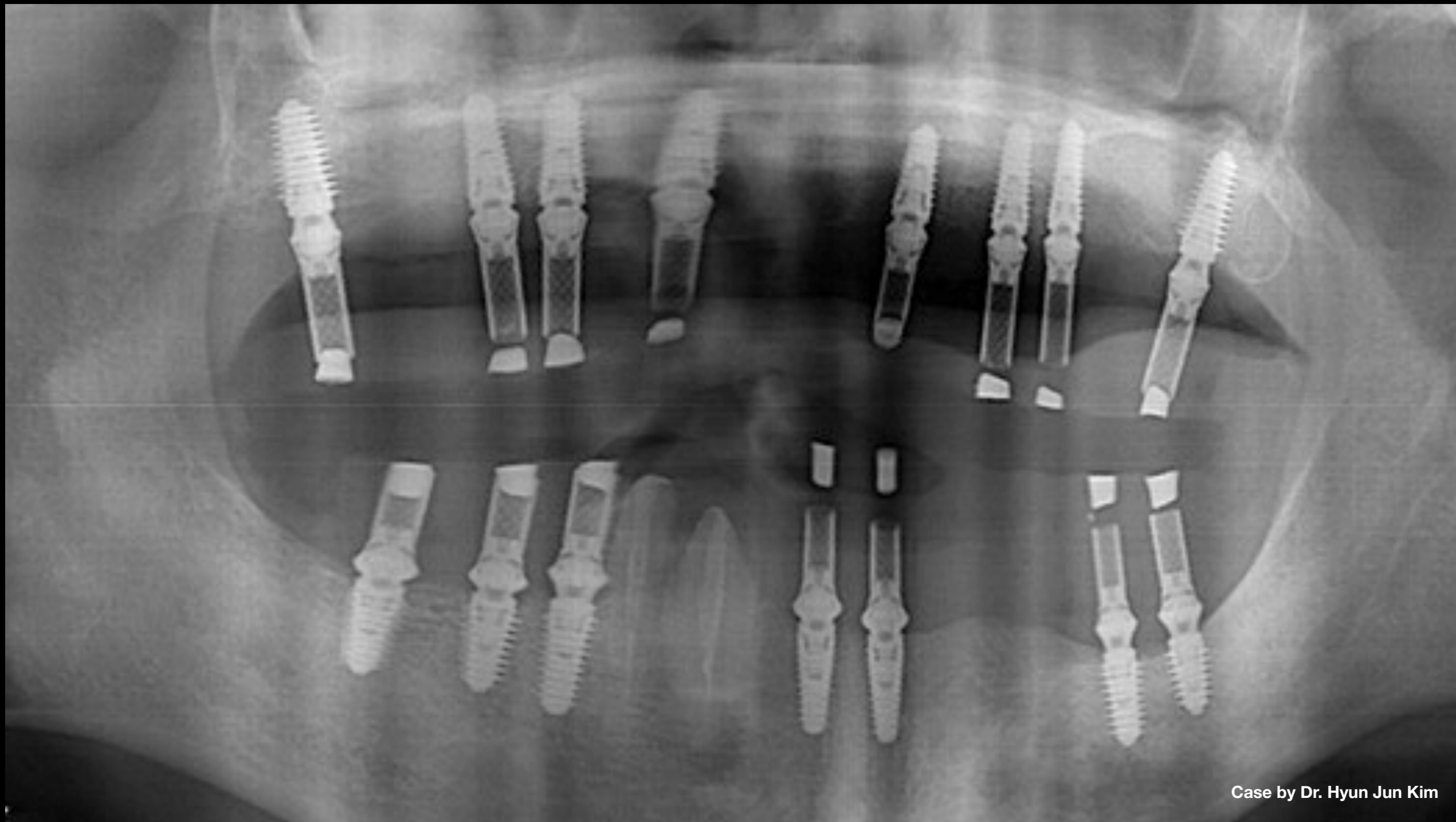
**Clinical Case:** Provisional delivery





Case by Dr. Hyun Jun Kim

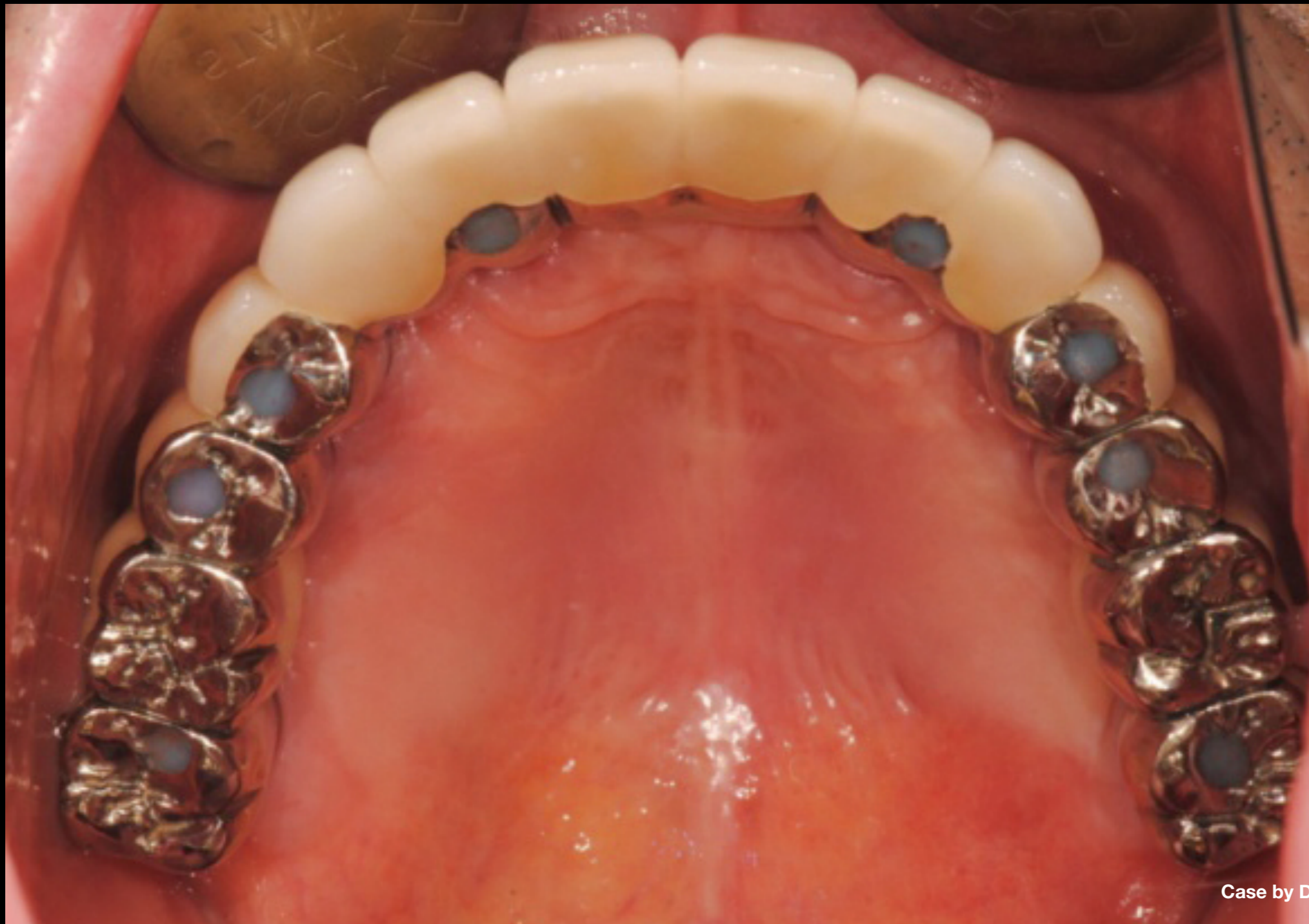**Clinical Case:** Provisional delivery



Case by Dr. Hyun Jun Kim

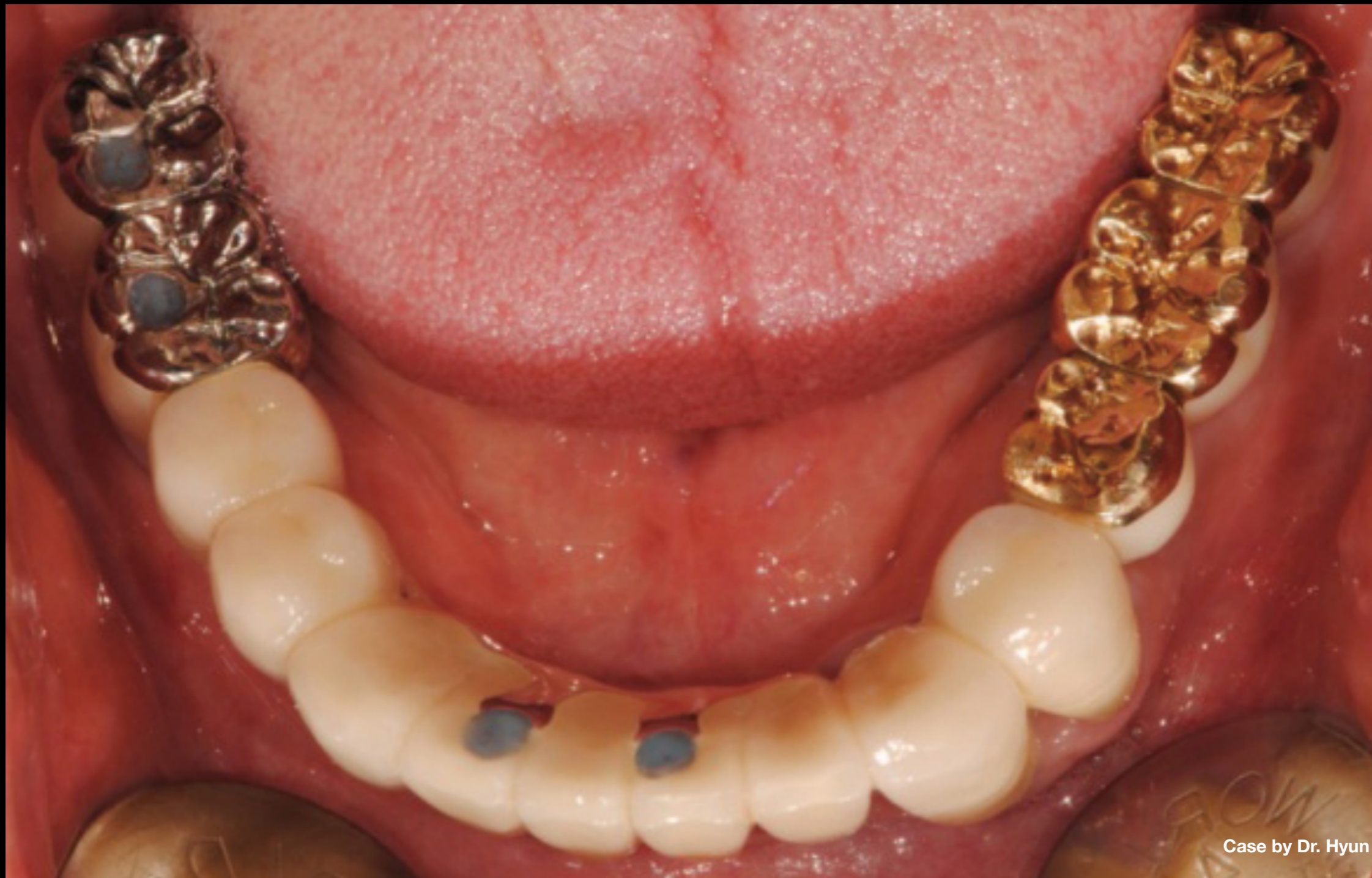**Clinical Case:** Panoramic scan after provisional delivery





Case by Dr. Hyun Jun Kim

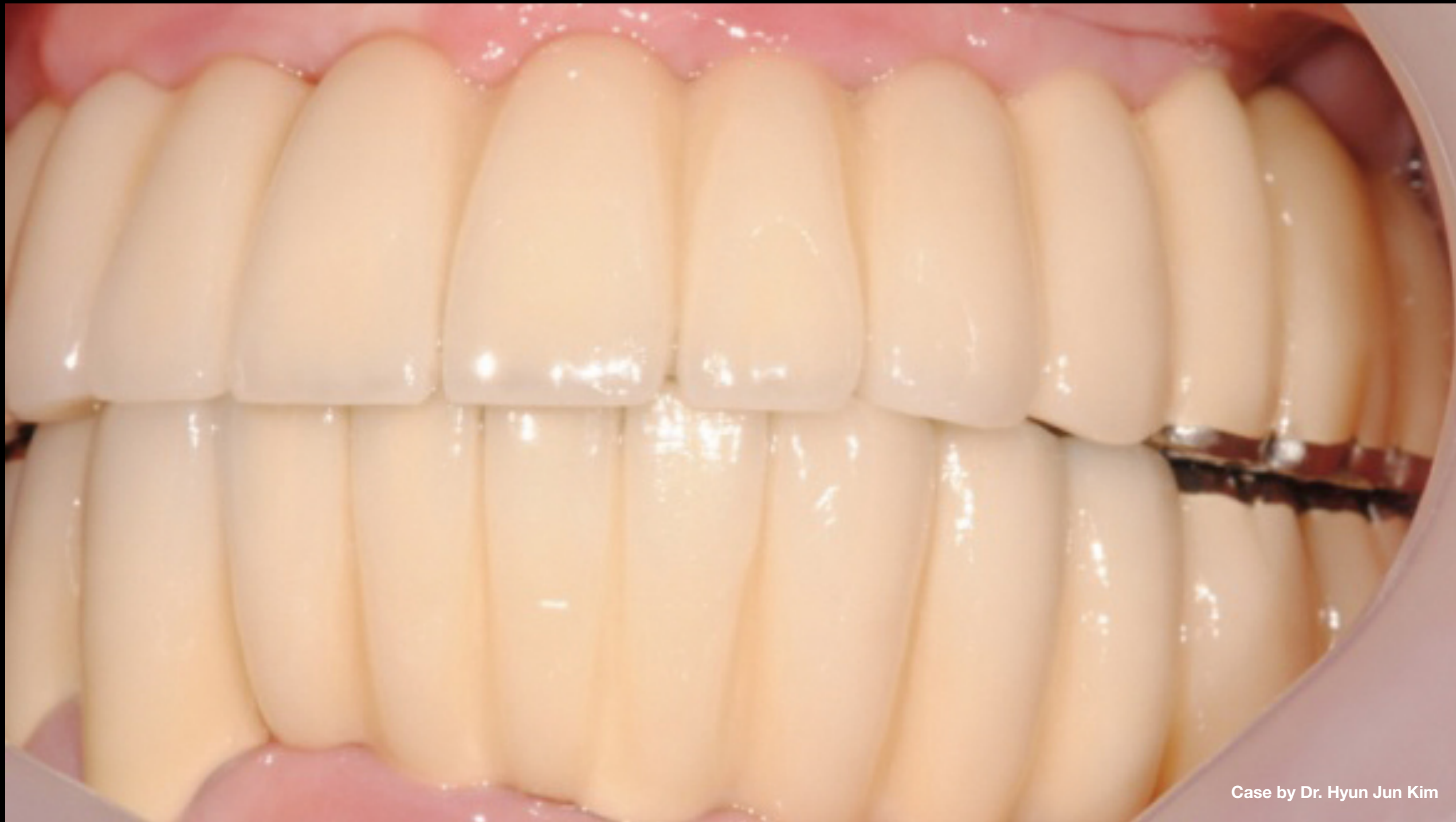**Clinical Case:** Due to height of posterior teeth & history of night bruxism, 1-unit restoration was made for cross-arch stabilization & gold occlusal surface used to avoid porcelain fractures



Case by Dr. Hyun Jun Kim

**Clinical Case:** Due to height of posterior teeth & history of night bruxism, 1-unit restoration was made for cross-arch stabilization & gold occlusal surface used to avoid porcelain fractures

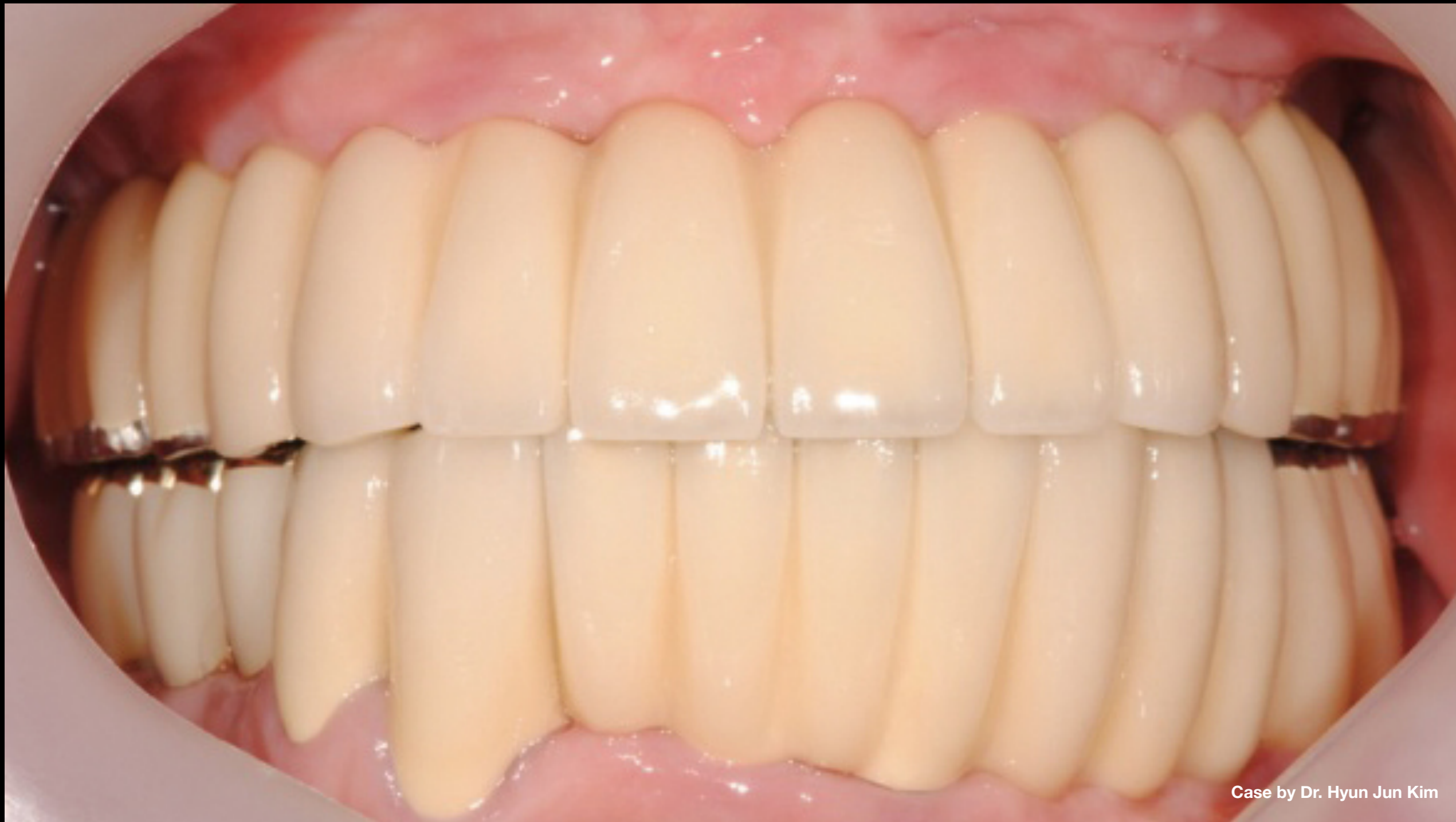



Case by Dr. Hyun Jun Kim

Clinical Case: Final loading

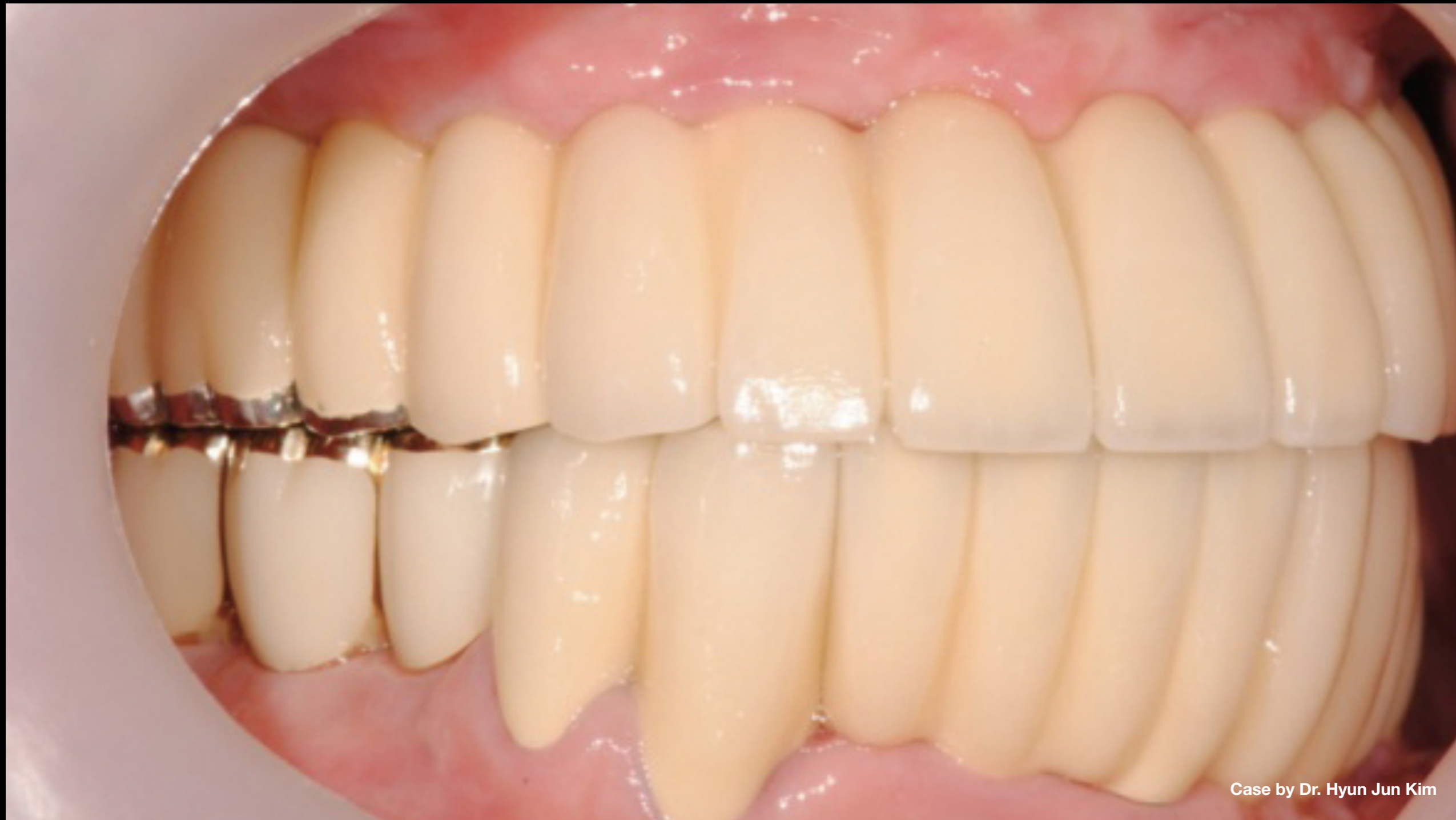



Case by Dr. Hyun Jun Kim

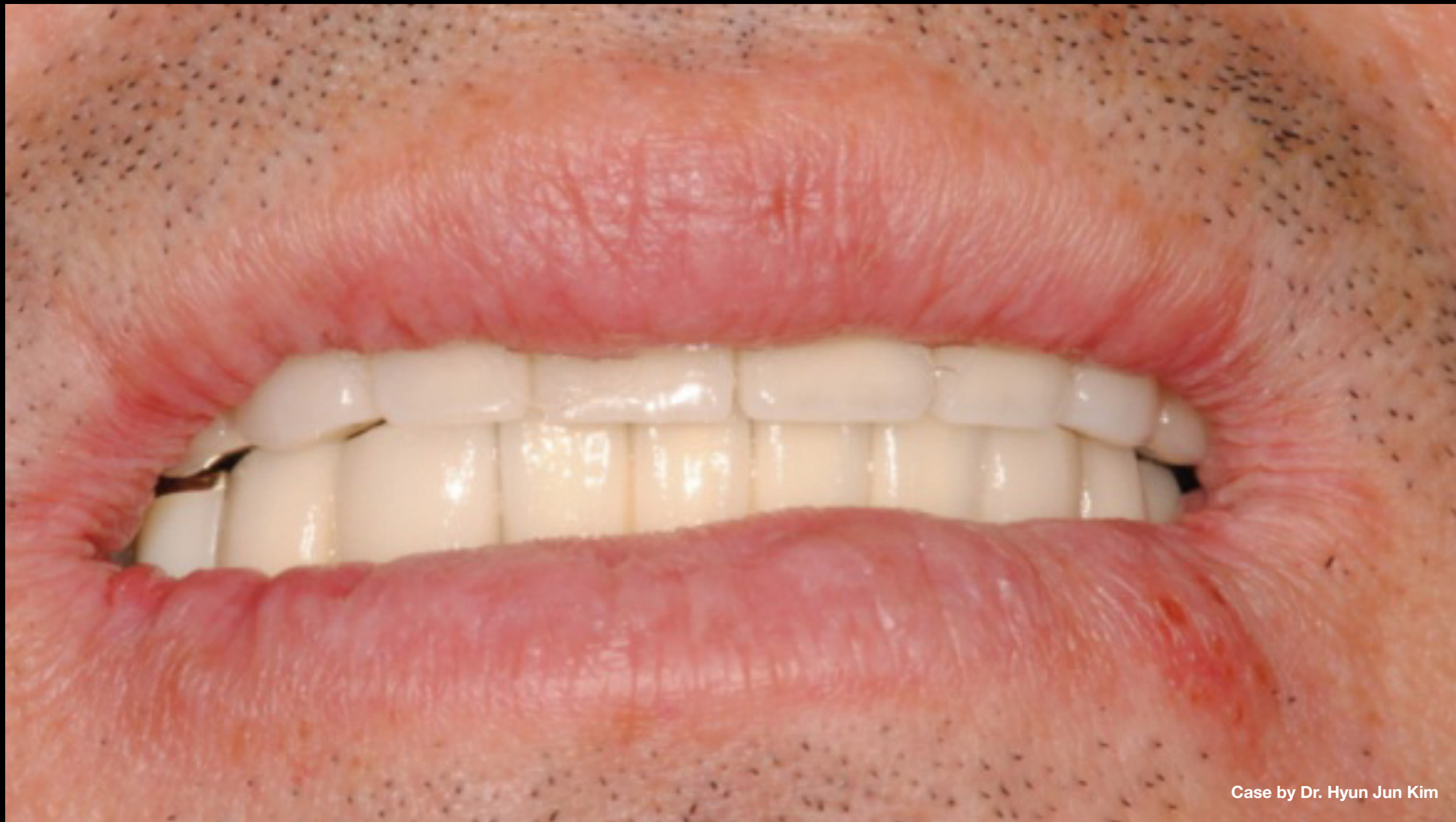**Clinical Case:** Final loading





Case by Dr. Hyun Jun Kim

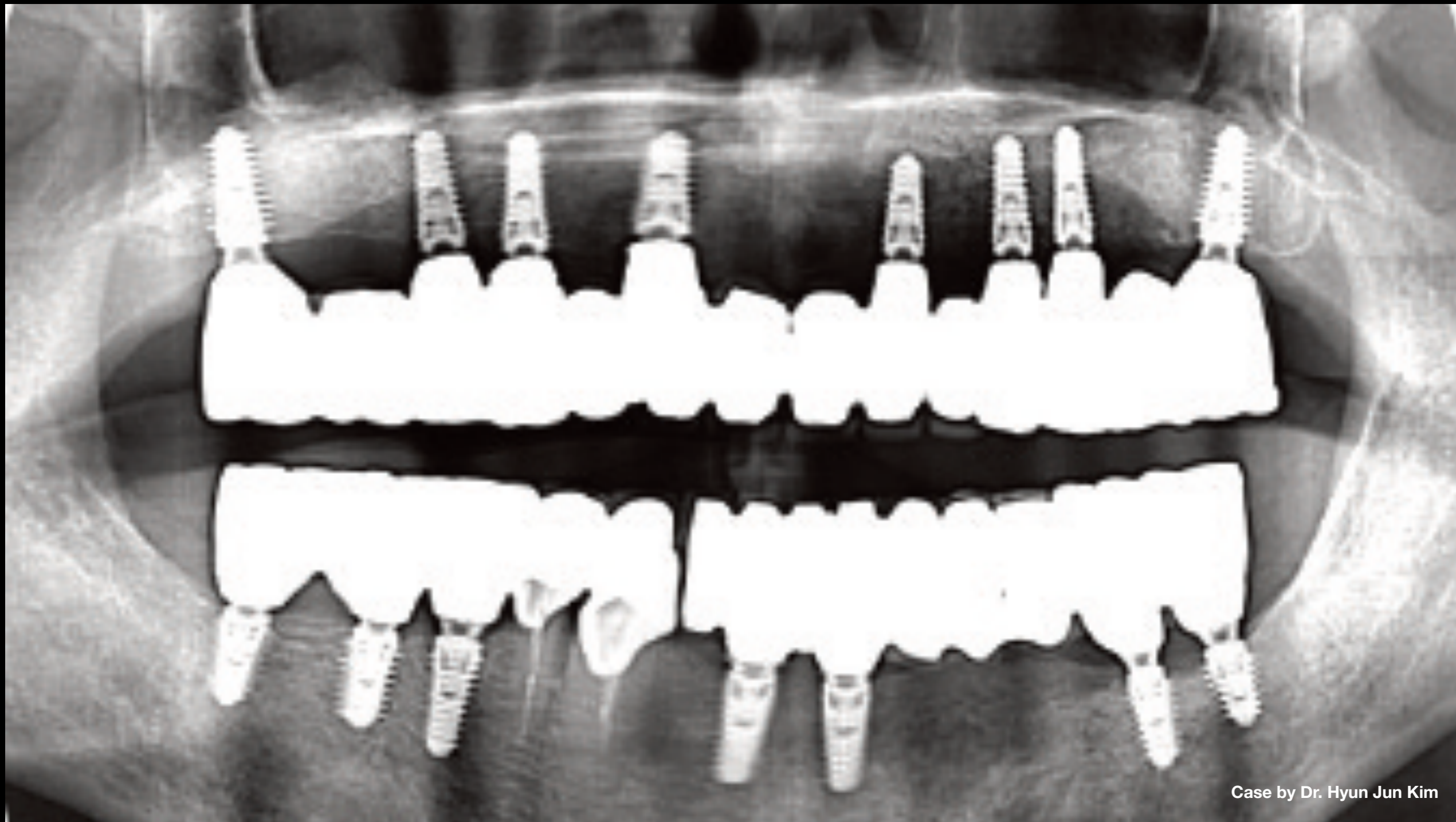
**Clinical Case:** Final loading



Case by Dr. Hyun Jun Kim

**Clinical Case:** Final loading



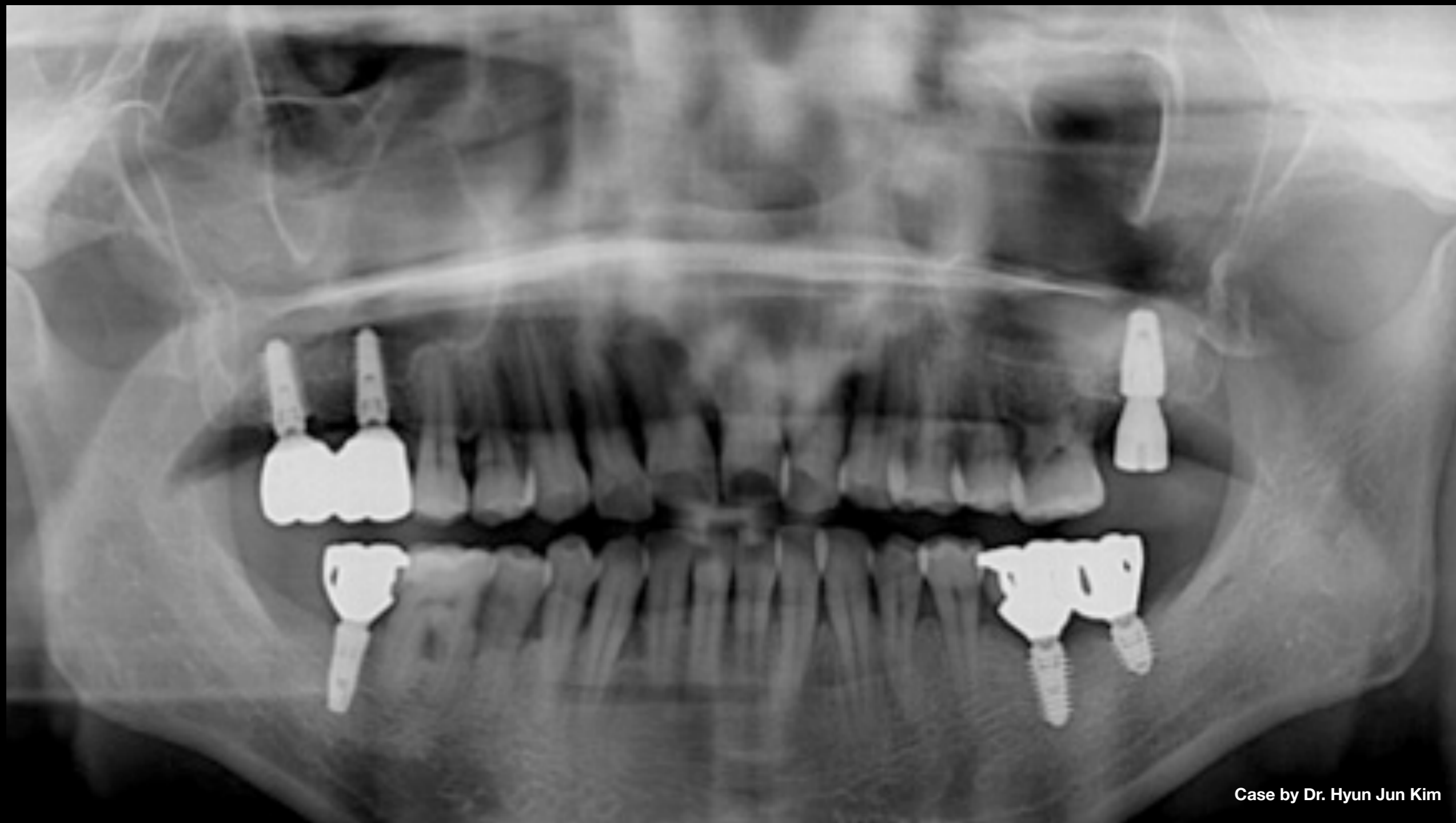

Case by Dr. Hyun Jun Kim

**Clinical Case:**

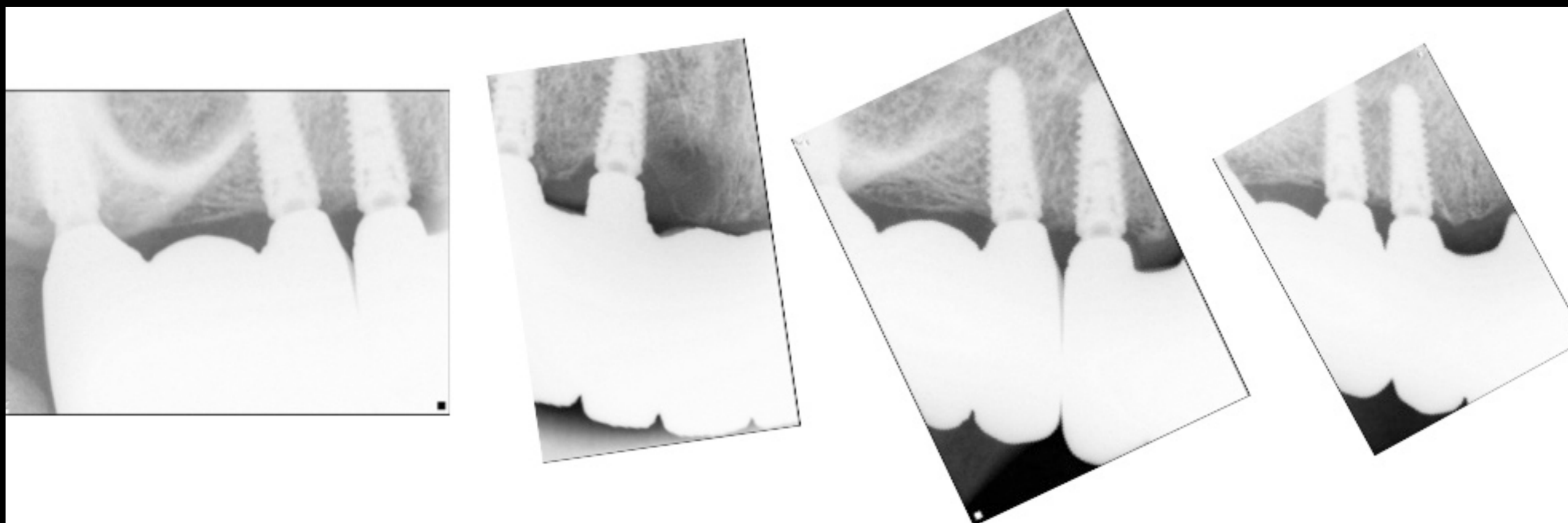
- Panoramic scan after final loading
- Due to frequent fractures of maxillary prosthesis caused by patient's bruxism, prosthesis was replaced with full zirconia, which resulted in no further fractures





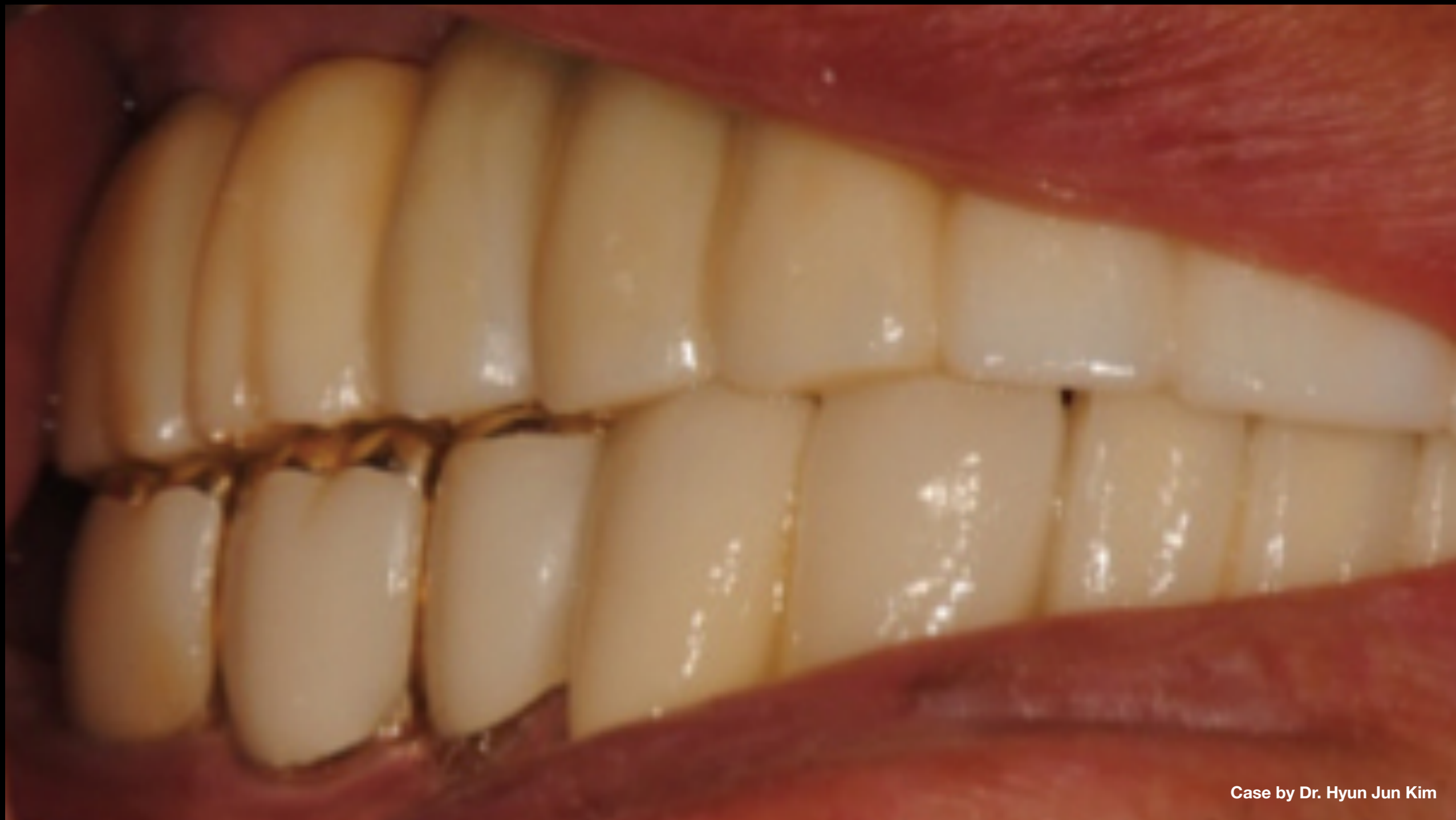Case by Dr. Hyun Jun Kim

**Clinical Case:** 5-yr follow-up panoramic scan after replacement with full-zirconia prosthesis



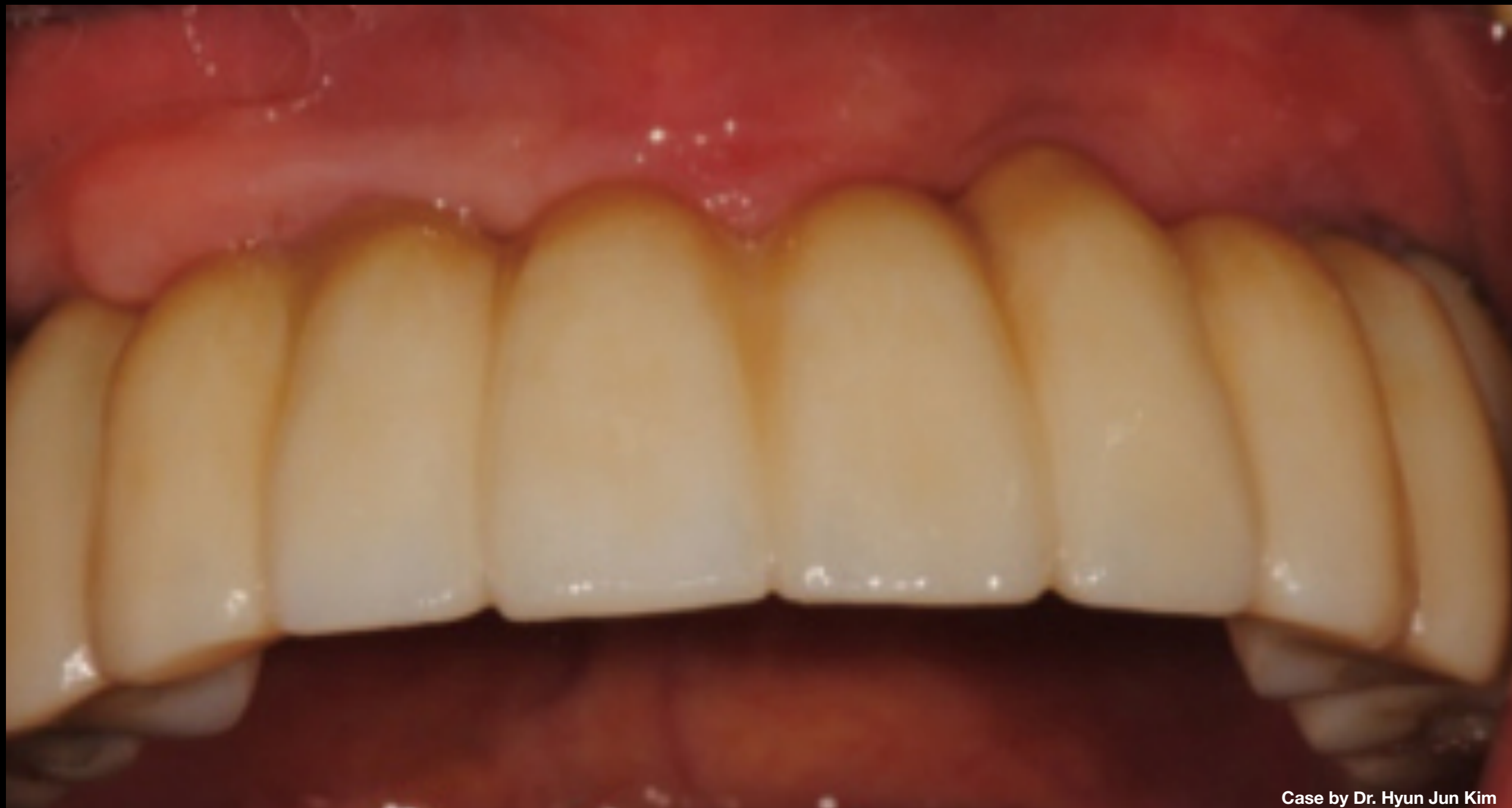Case by Dr. Hyun Jun Kim

**Clinical Case:** 5-yr follow-up intraoral scan after replacement with full-zirconia prosthesis



Case by Dr. Hyun Jun Kim

**Clinical Case:** 5-yr follow-up photos after replacement with full-zirconia prosthesis



Case by Dr. Hyun Jun Kim

**Clinical Case:** 5-yr follow-up photos after replacement with full-zirconia prosthesis

