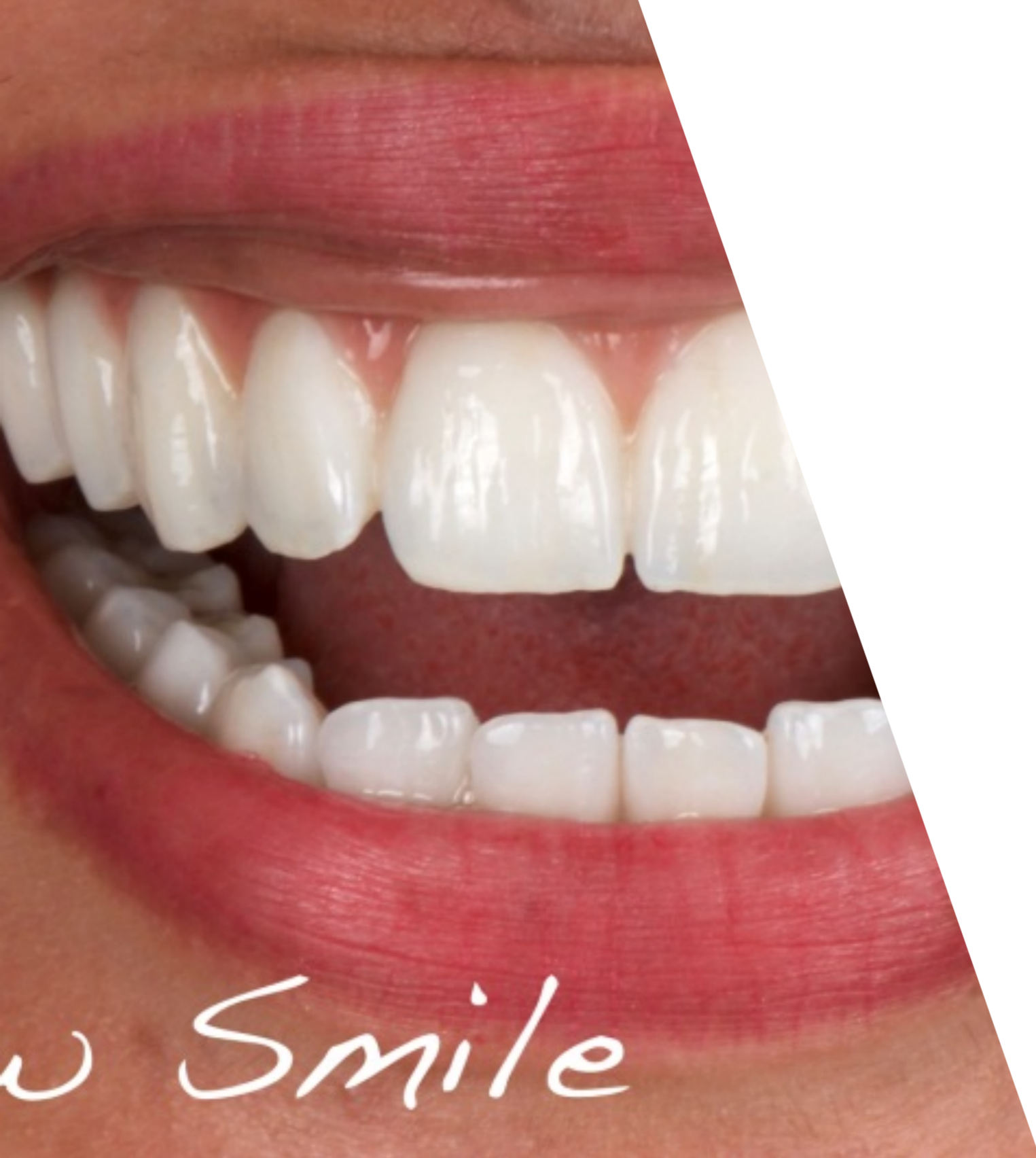
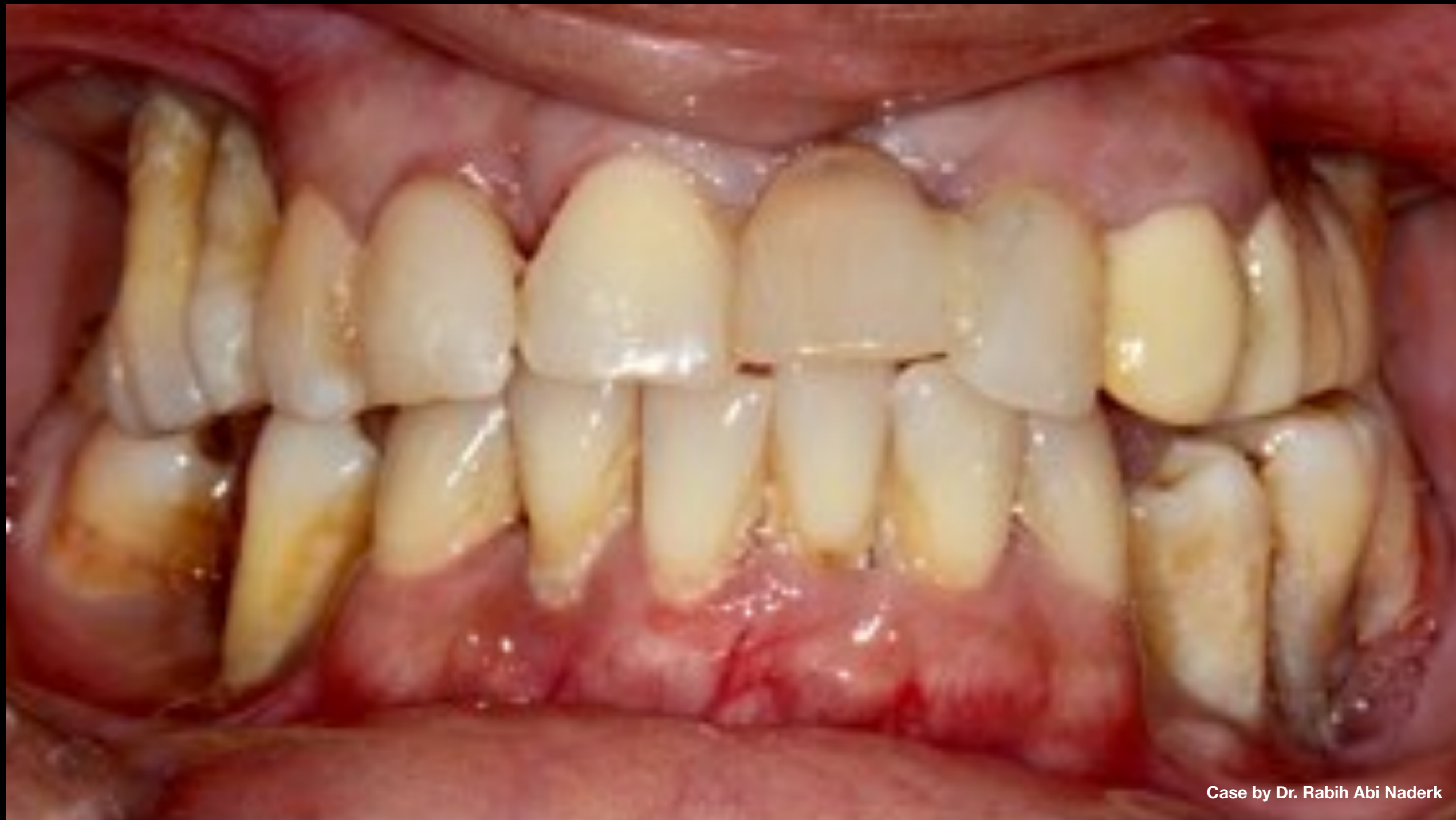


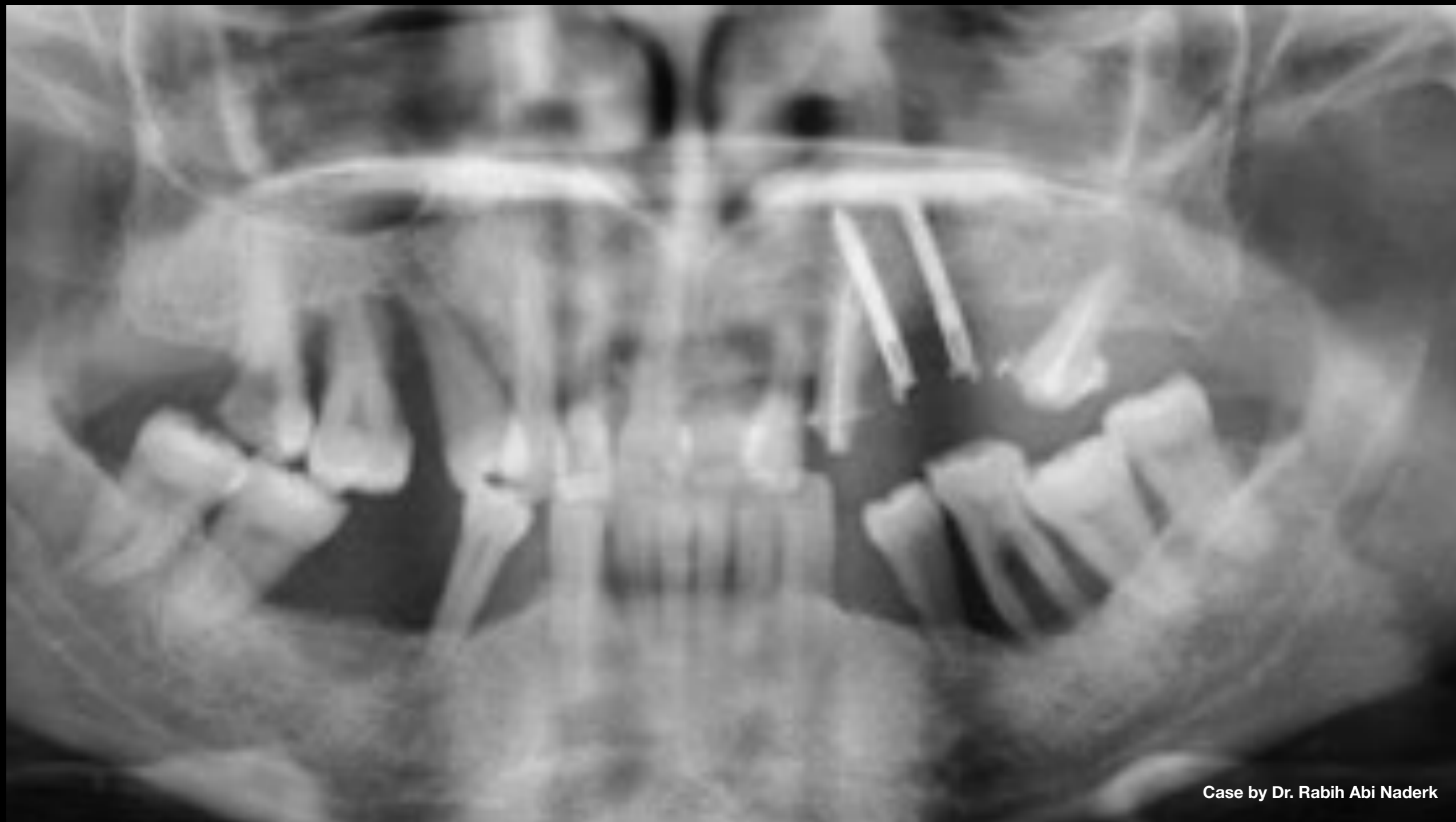Full transition from natural teeth to all-on-6 bridges with AnyRidge implants

Dr. Rabih Abi Nader



Case by Dr. Rabih Abi Naderk

Clinical Case: Photo before surgery

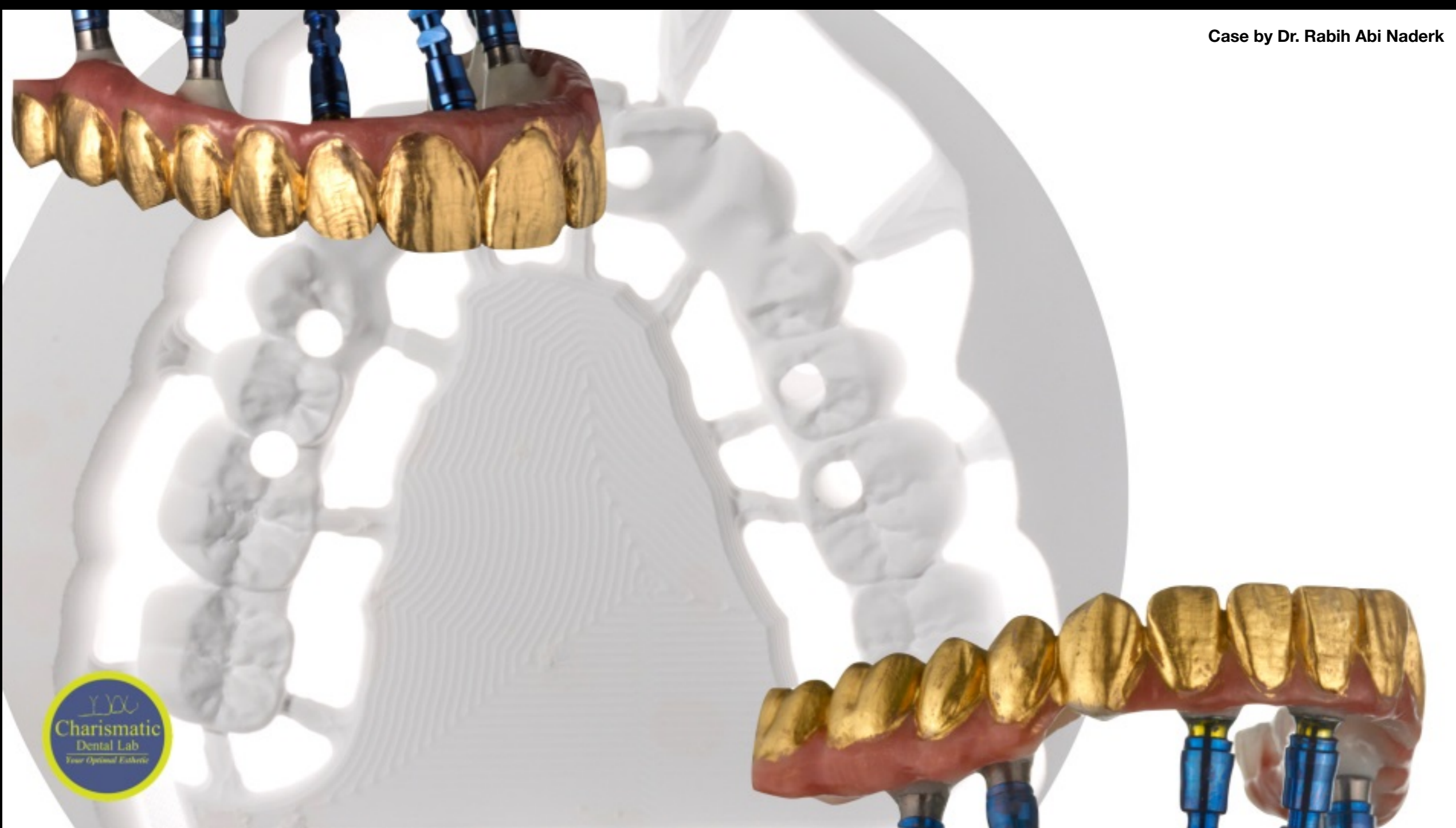


Case by Dr. Rabih Abi Naderk

Clinical Case: Panoramic scan before surgery



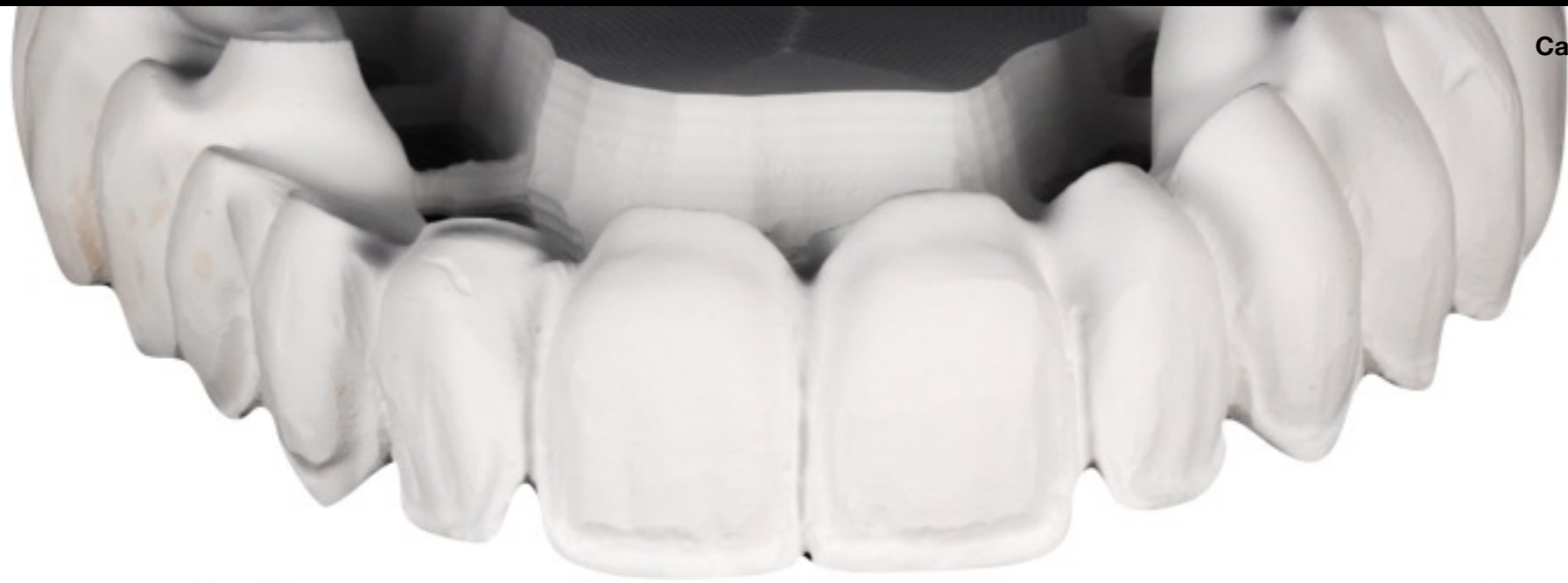Case by Dr. Rabih Abi Naderk



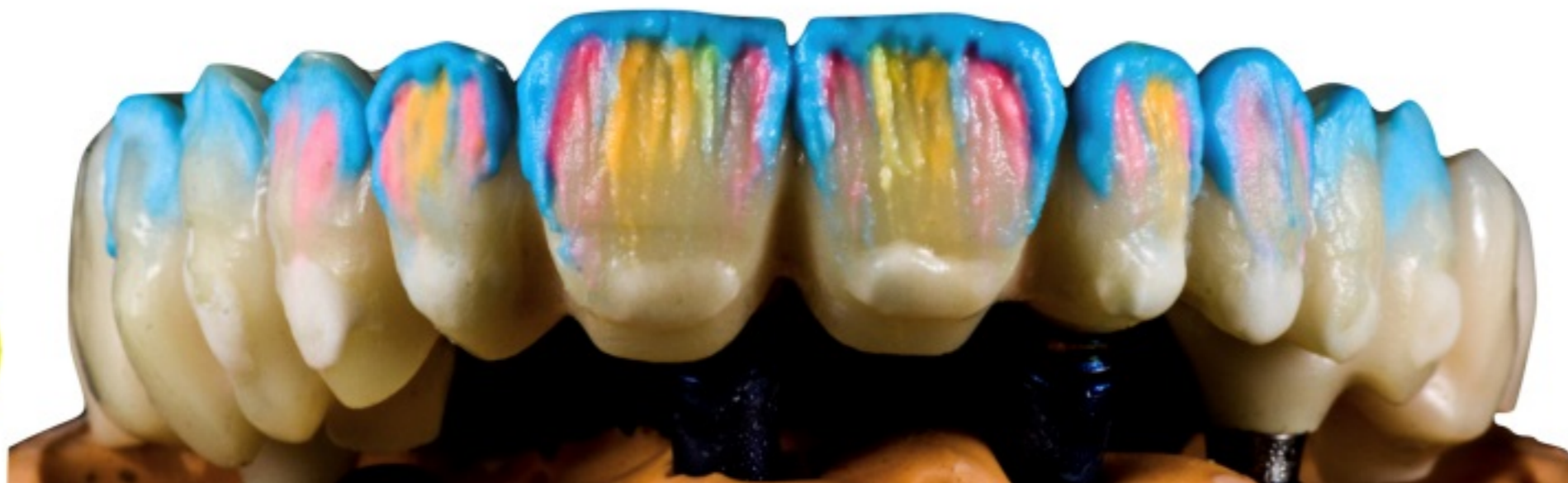Clinical Case: Minimal layering, Zirconia up to incisal edge



Case by Dr. Rabih Abi Naderk

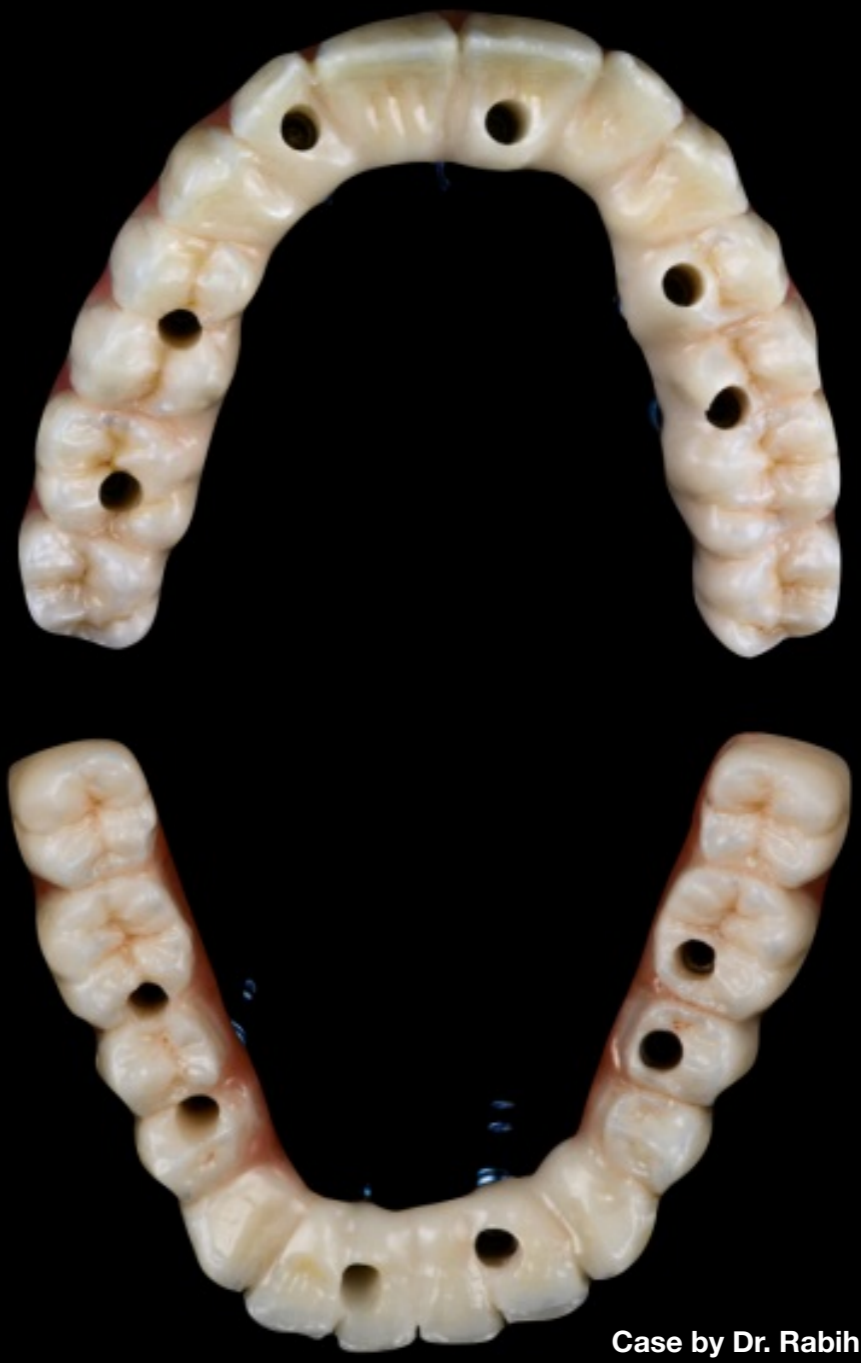
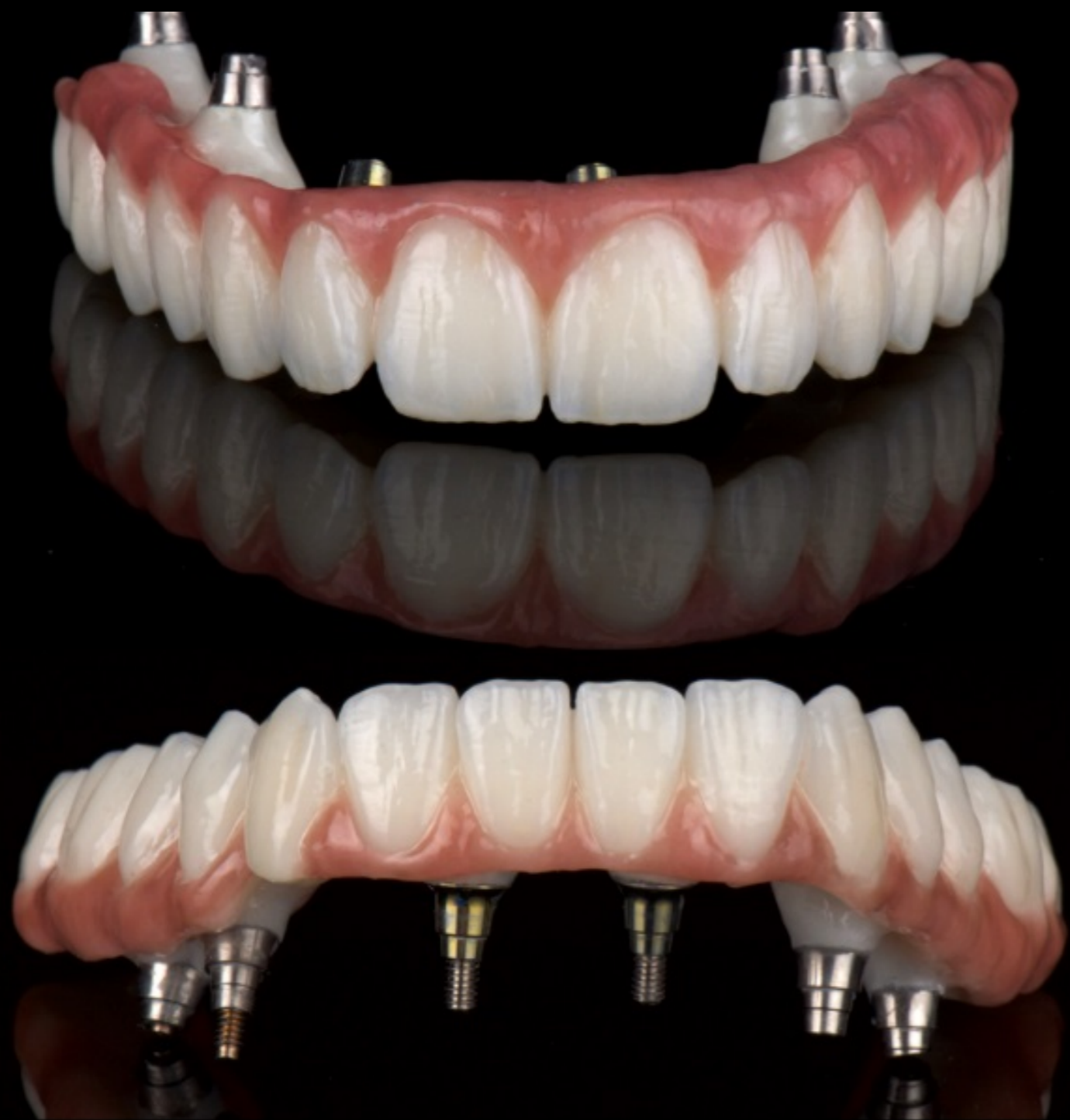
Minimal layering, Zirconia up to the incisal edge



Clinical Case: Minimal layering, Zirconia up to incisal edge

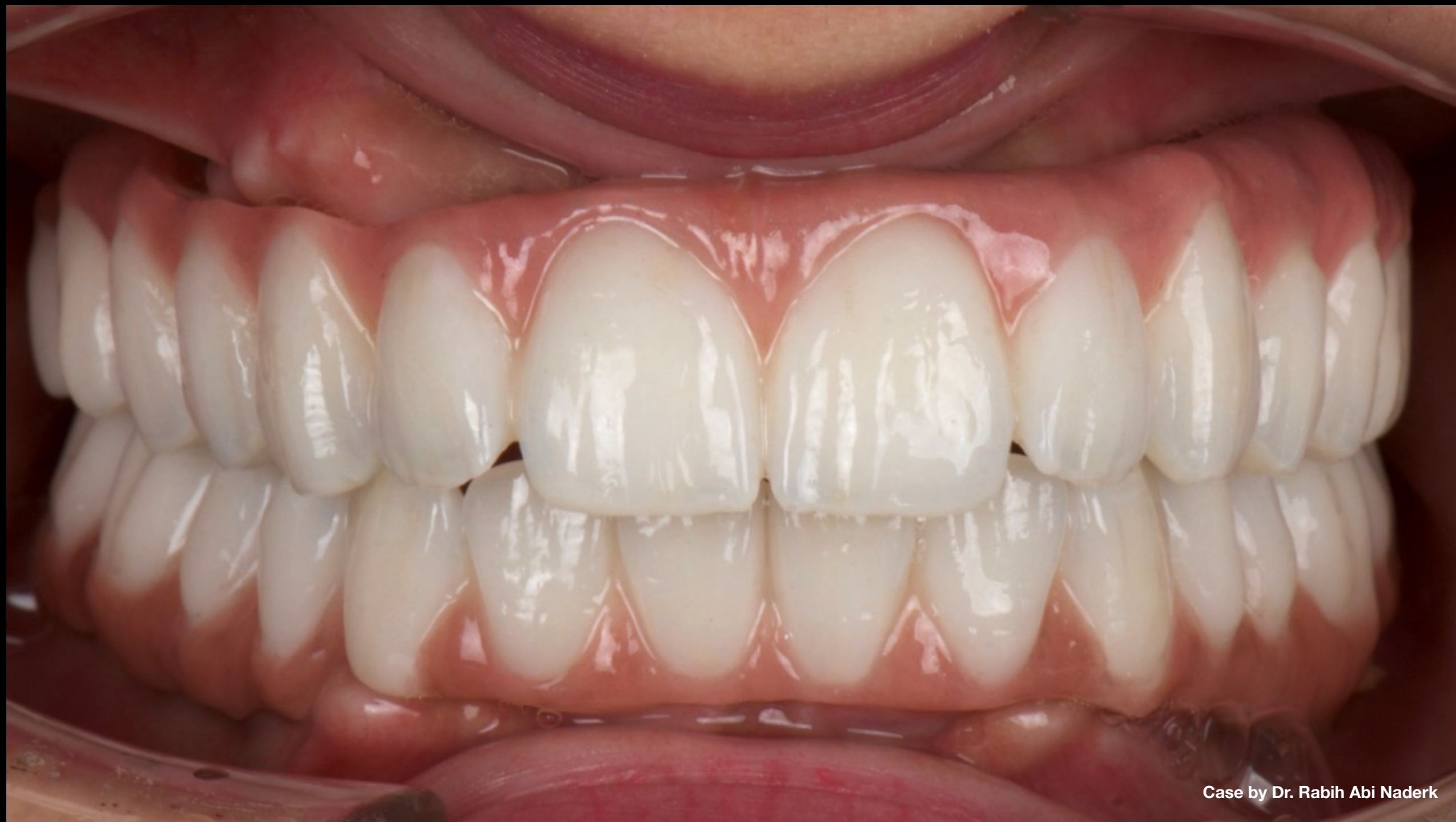



Clinical Case: Full zirconia all-on-6 dentures

Case by Dr. Rabihi Naderk

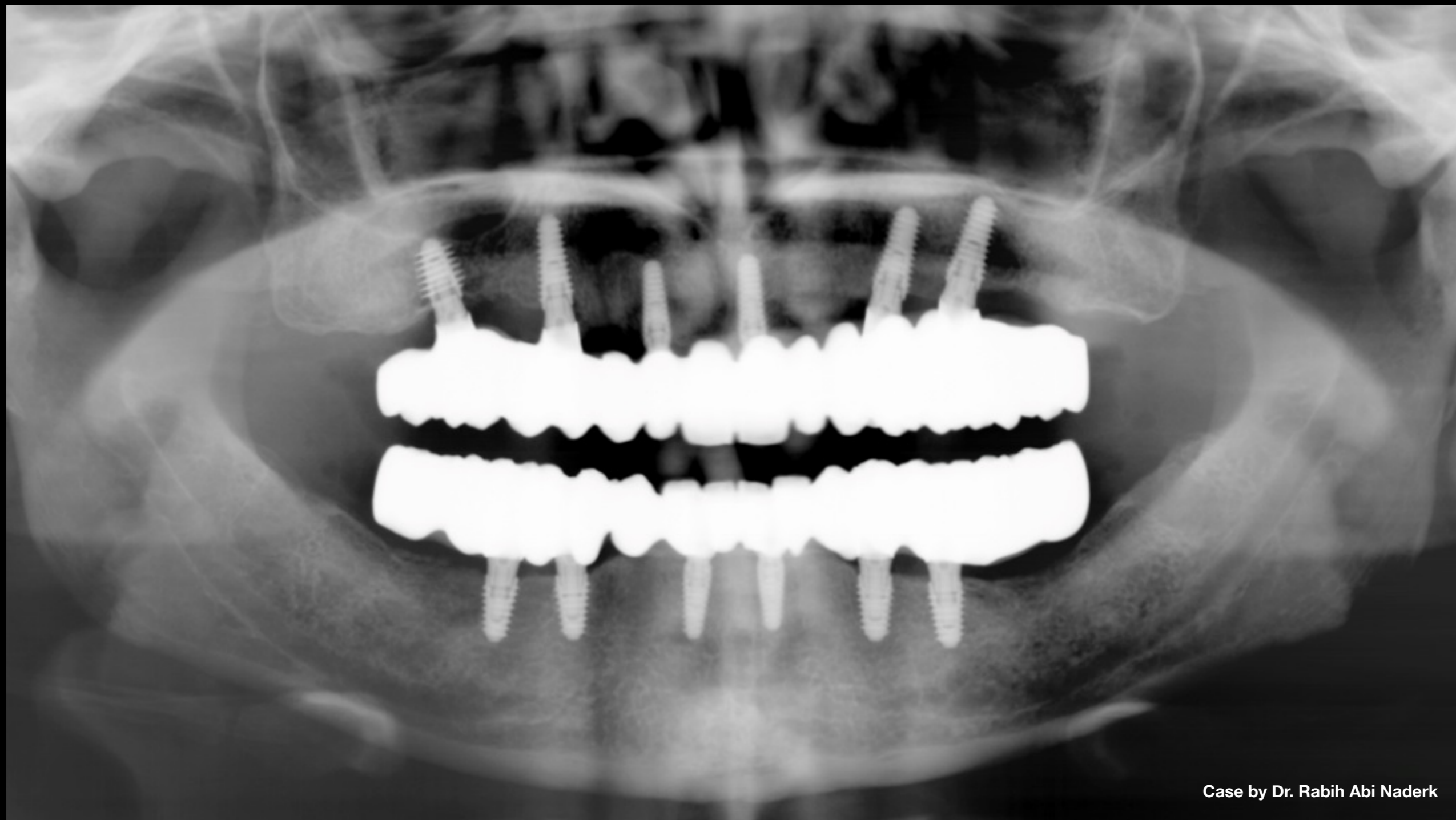




Case by Dr. Rabihi Abi Naderk

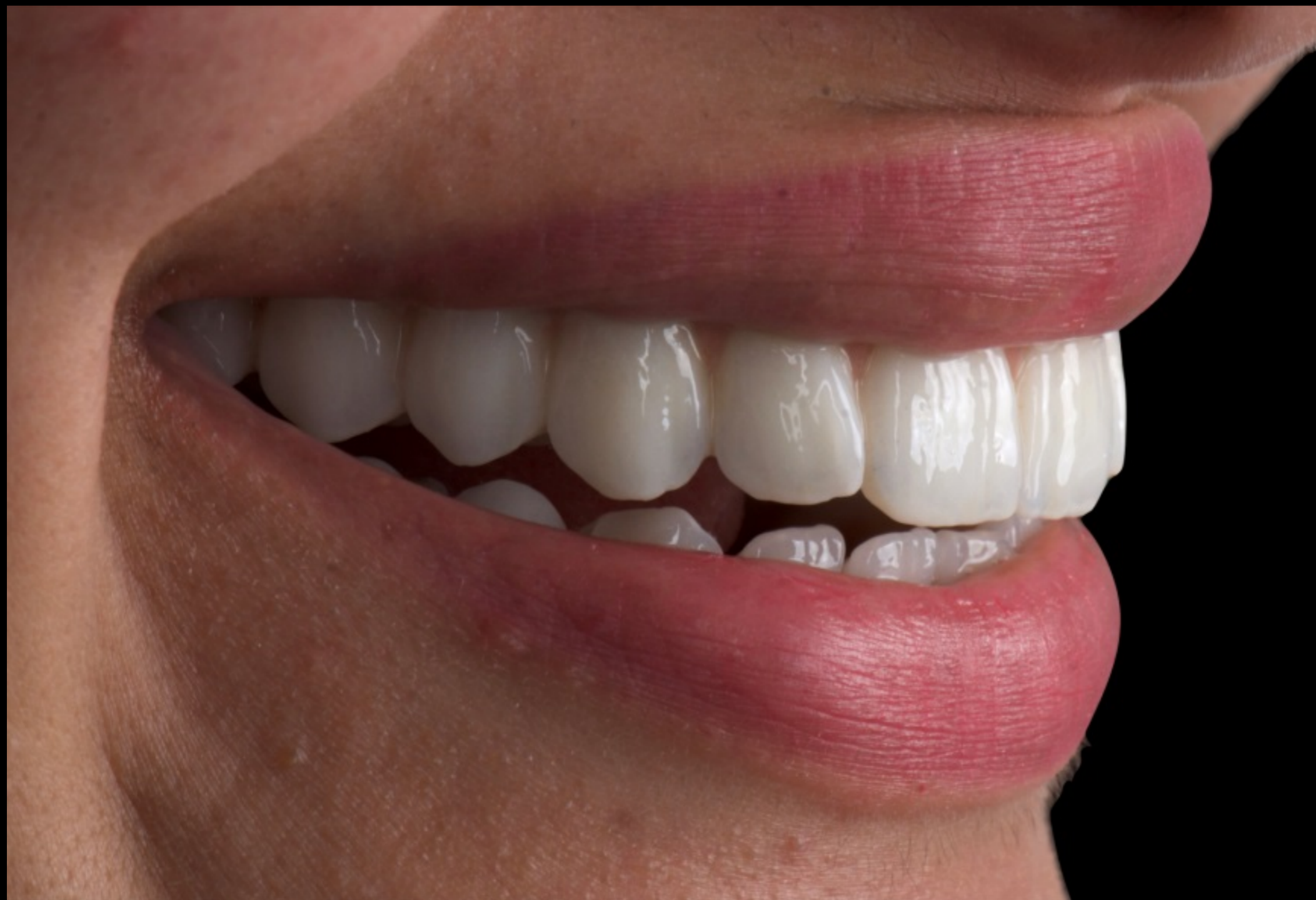Clinical Case: Final prosthesis completed





Case by Dr. Rabi Naderk

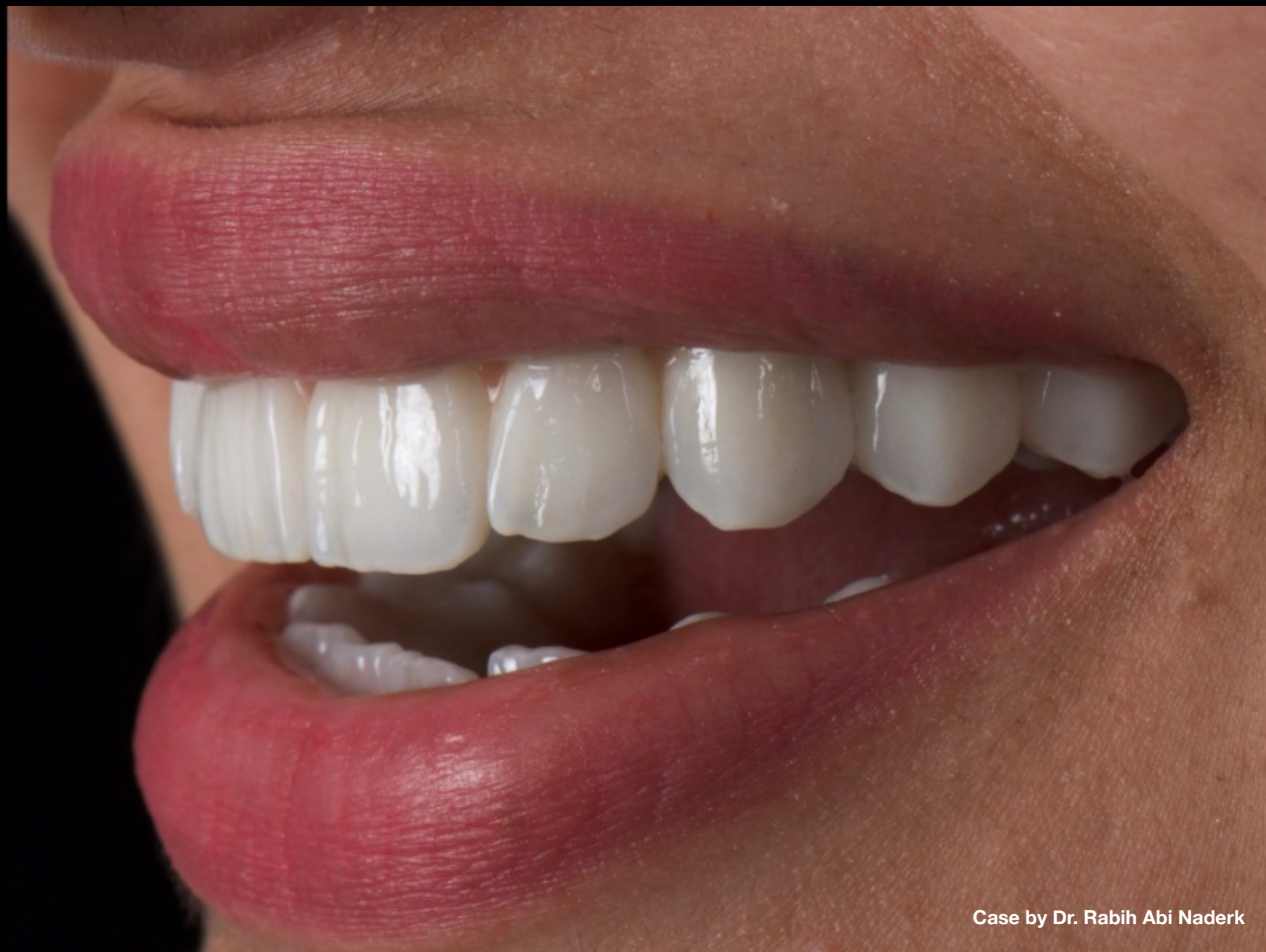Clinical Case: Panoramic scan of final restorations on day of delivery



Case by Dr. Rabih Abi Naderk

Clinical Case: Life changing result... first time eating apples in years

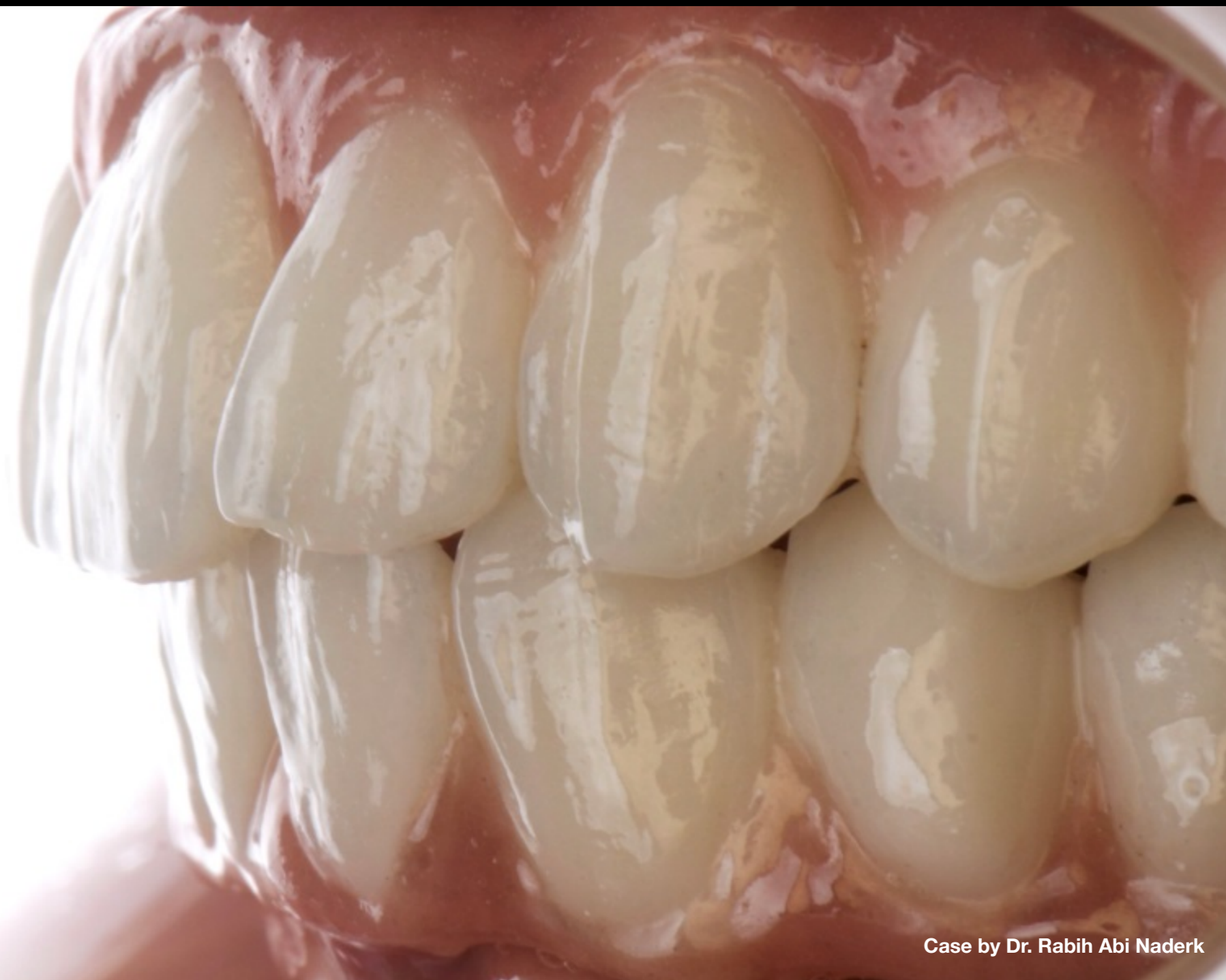



Case by Dr. Rabih Abi Naderk

Clinical Case: Life changing result... first time eating apples in years





Case by Dr. Rabi Naderk

Clinical Case: Life changing result... first time eating apples in years



