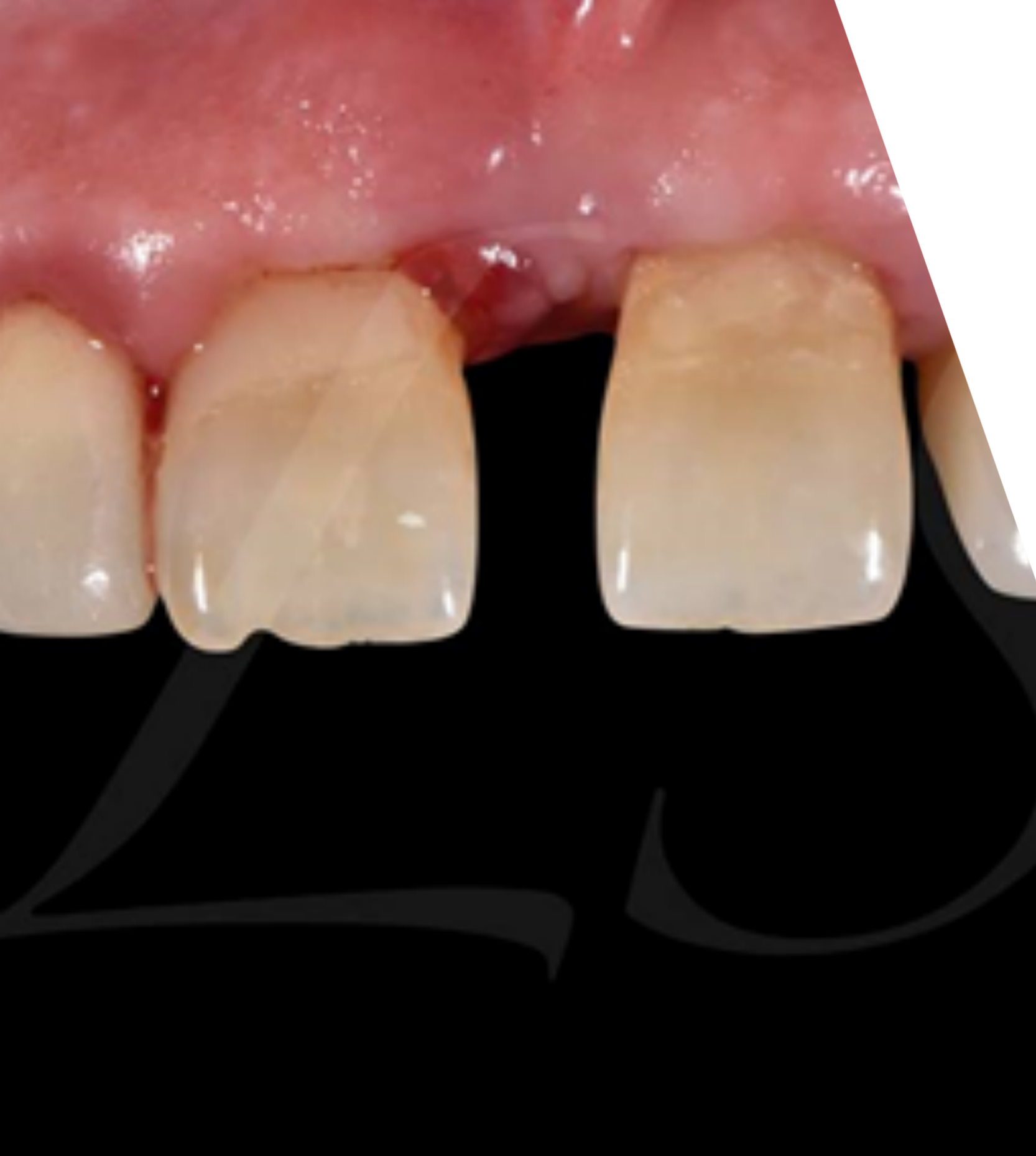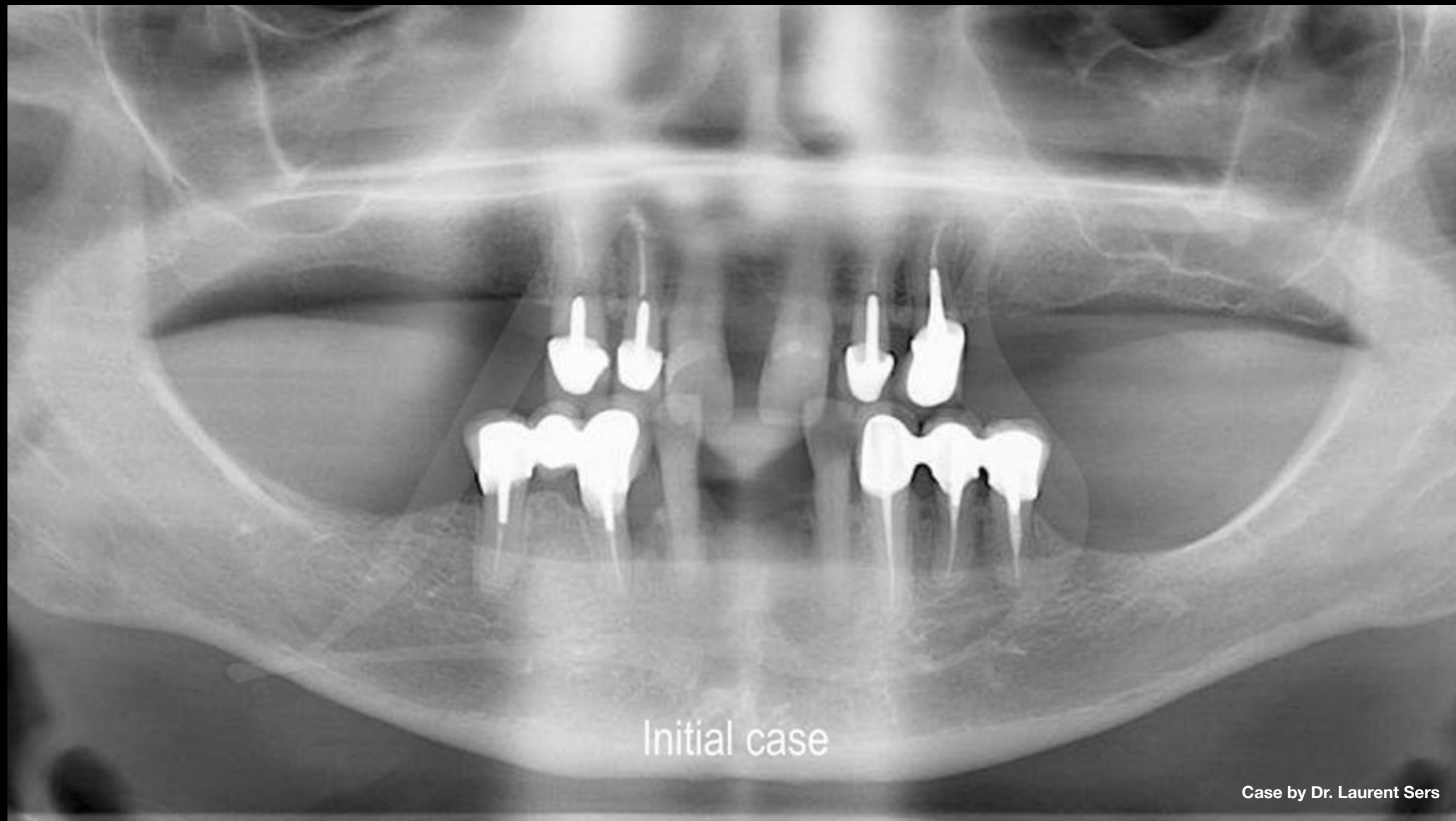


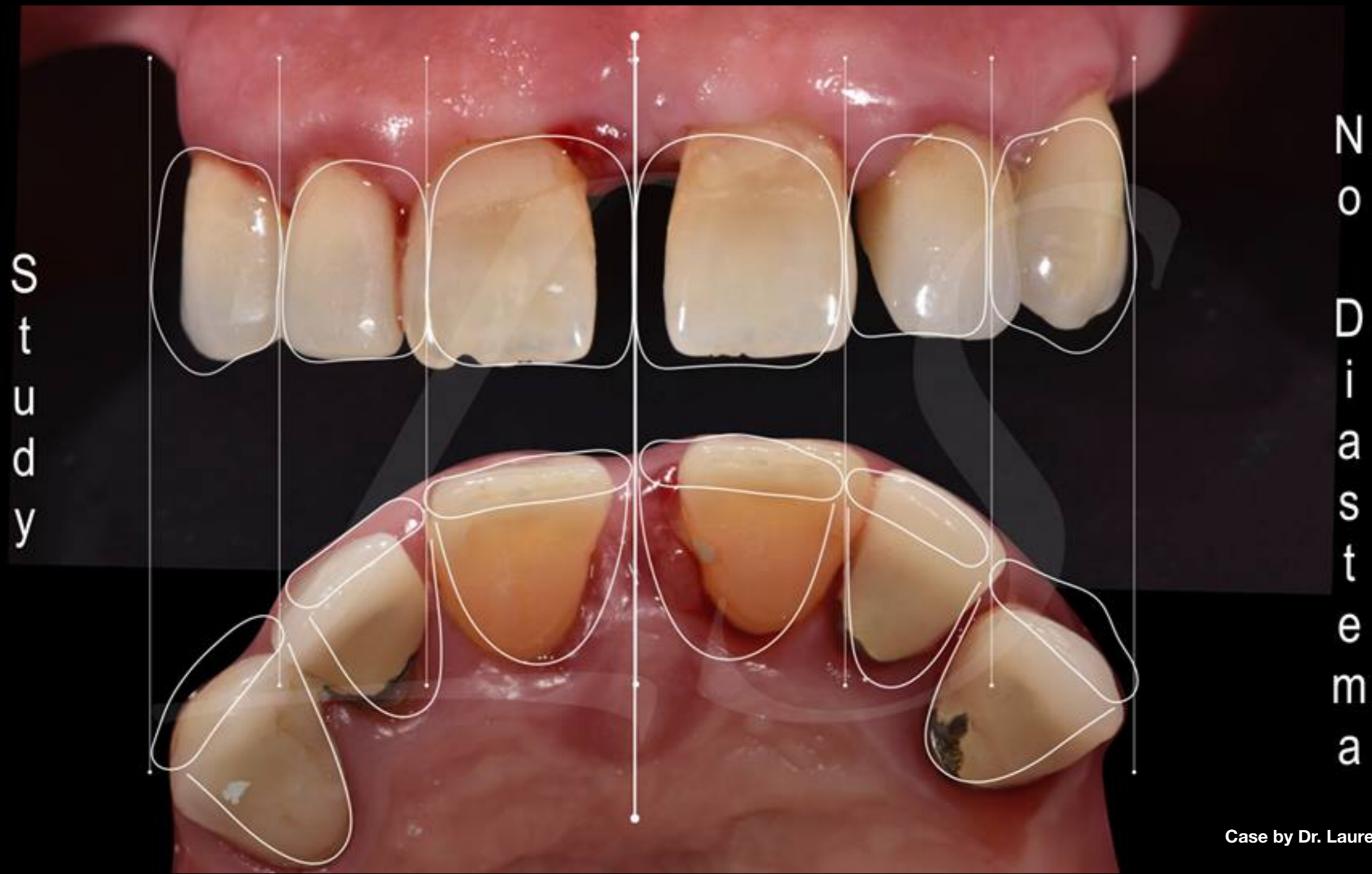


Full-arch implant treatment with  
immediate loading & extraction  
implantation

Dr. Laurent Sers

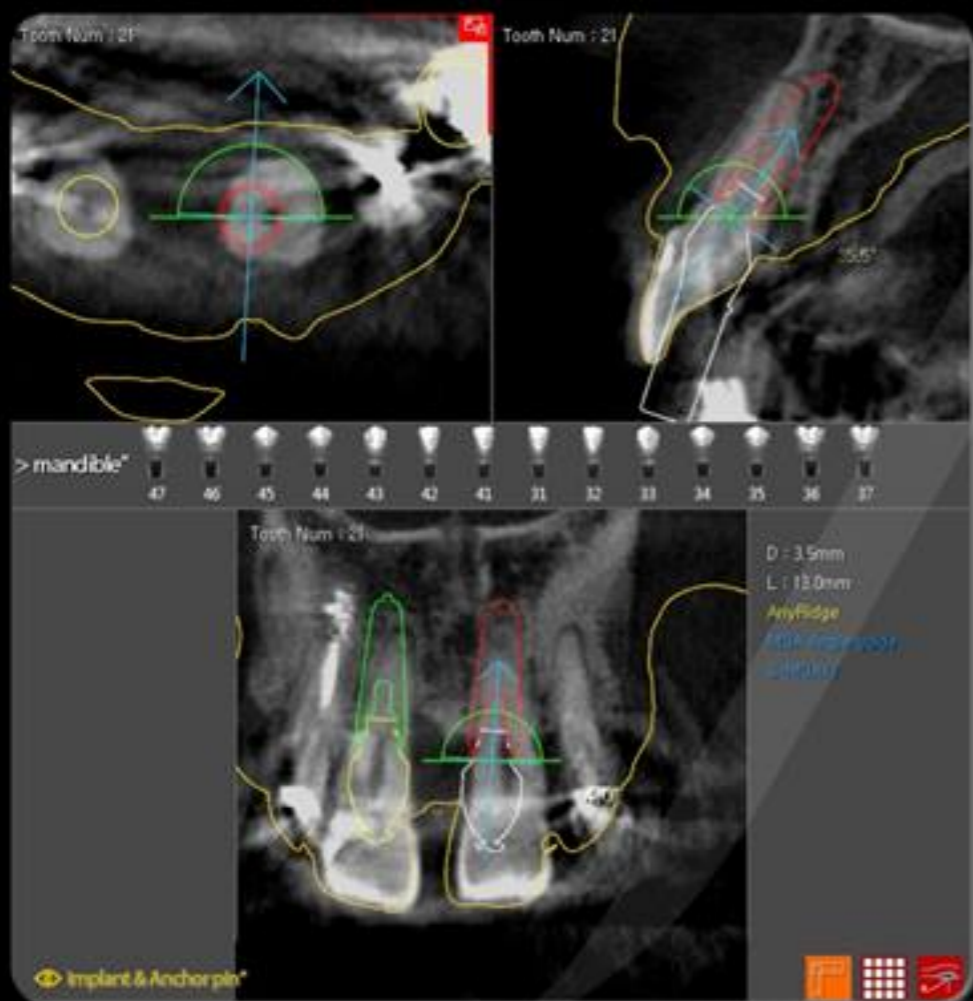


**Clinical Case:** Initial situation




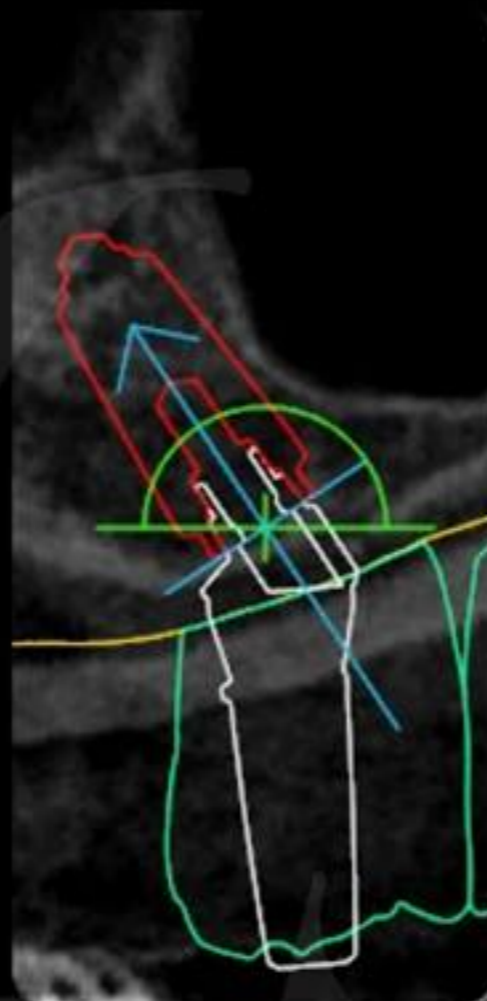
Clinical Case: No Diastema study

Case by Dr. Laurent Sers



Planning implant

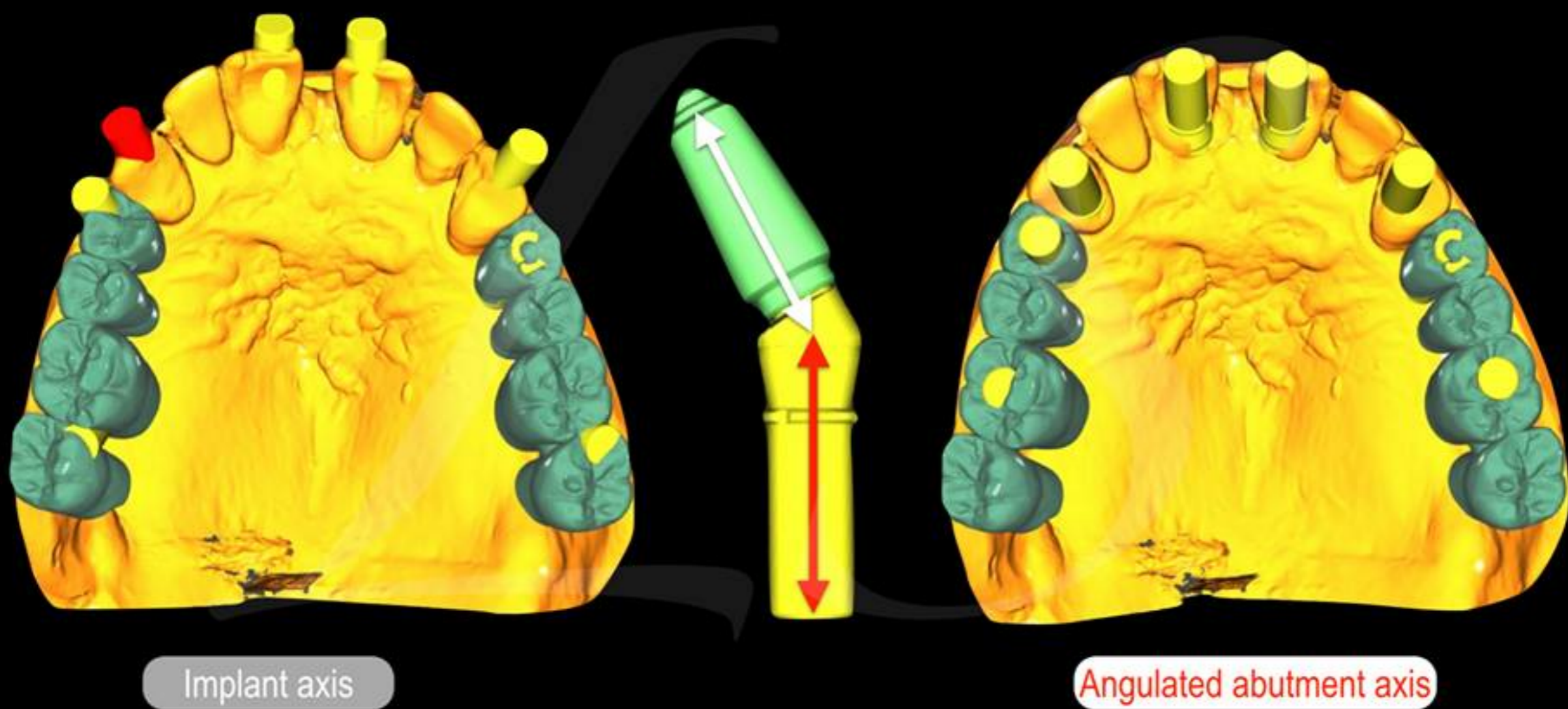
Clinical Case: Treatment planning using R2GATE



Planning and bone density value

Case by Dr. Laurent Sers

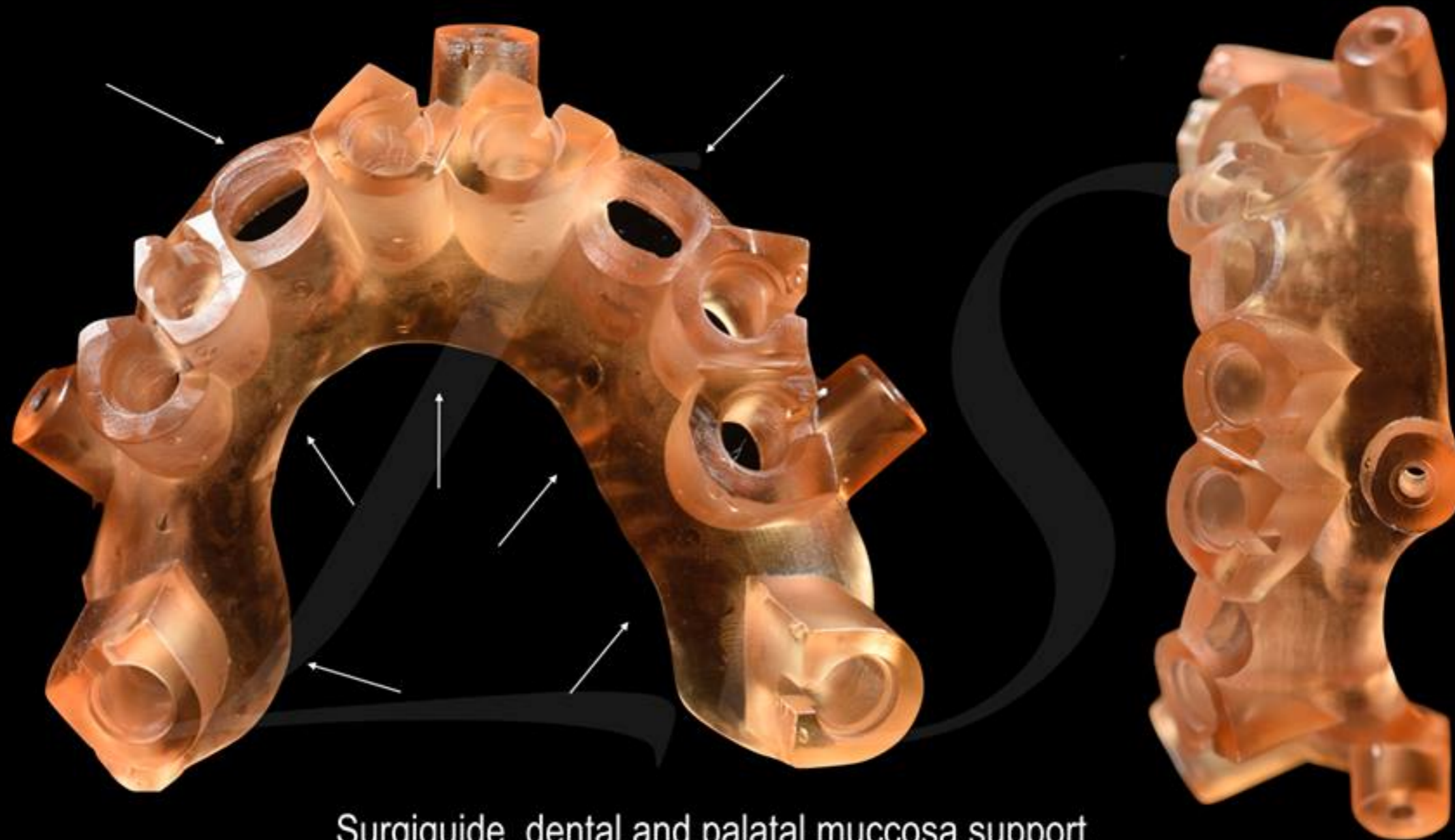




Case by Dr. Laurent Sers

Clinical Case: Treatment planning using R2GATE

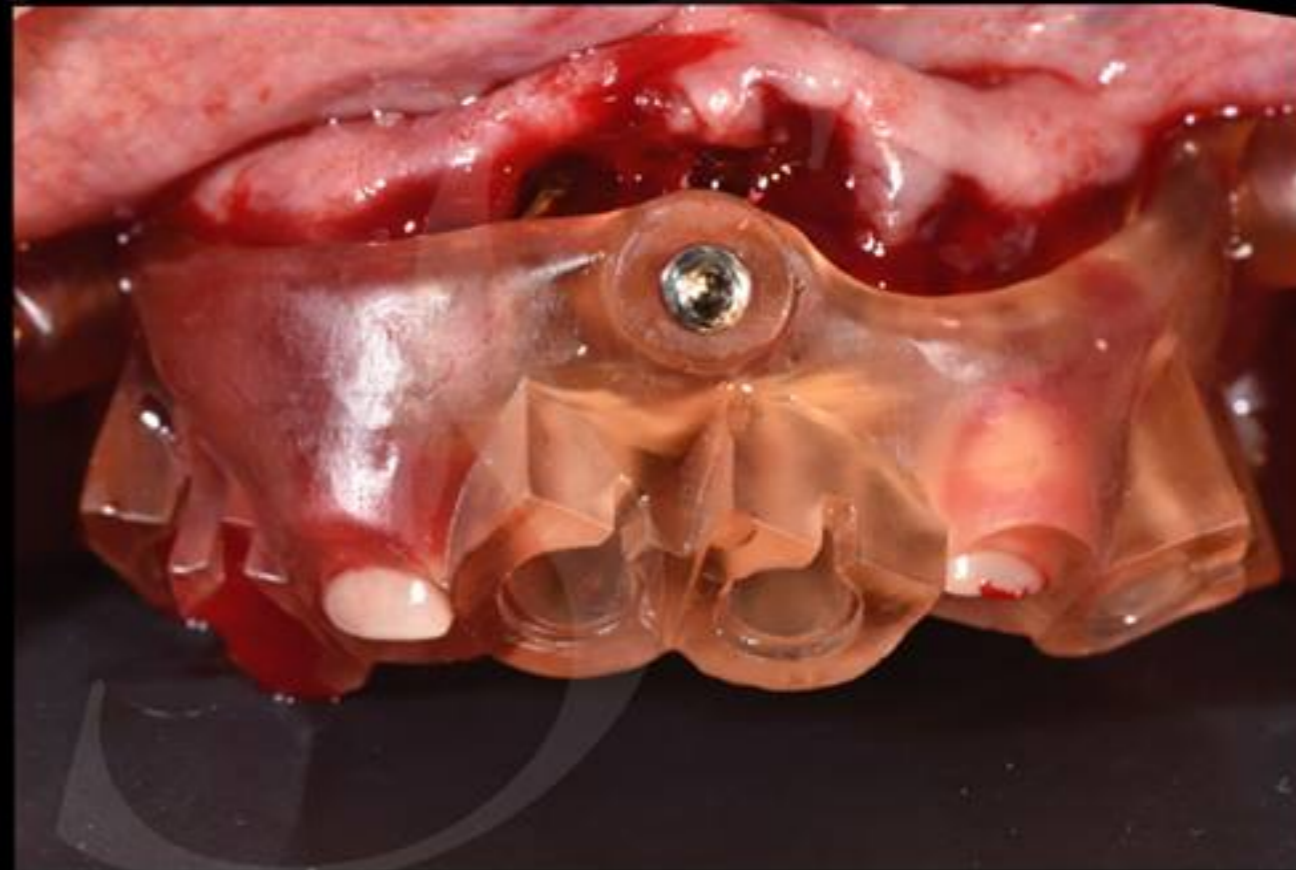
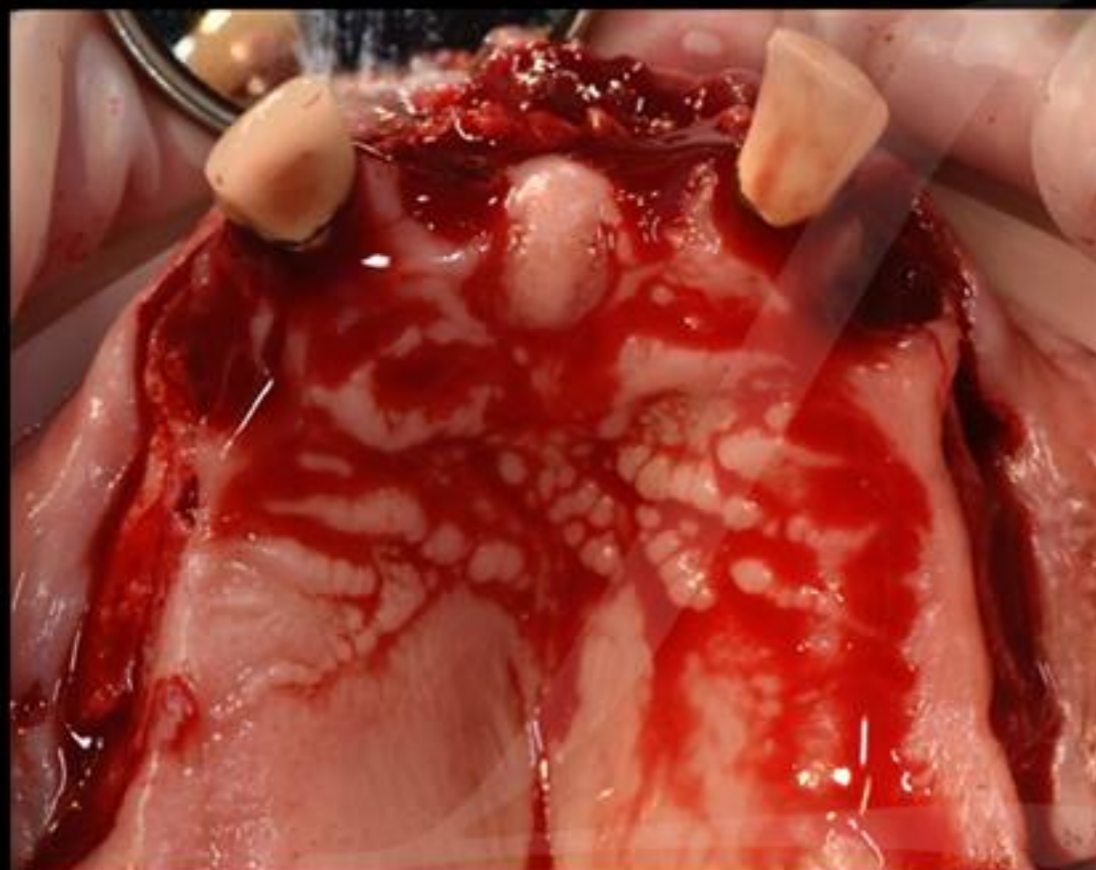



Surgiguide dental and palatal mucosa support

Case by Dr. Laurent Sers

Clinical Case: R2GATE Guide

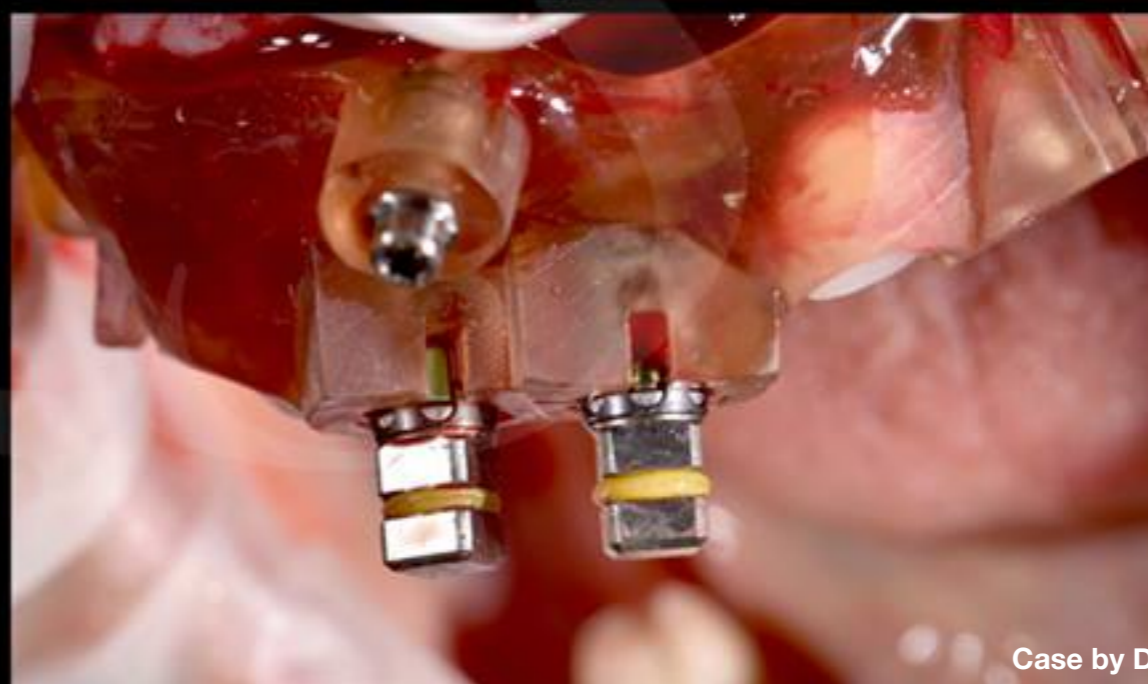
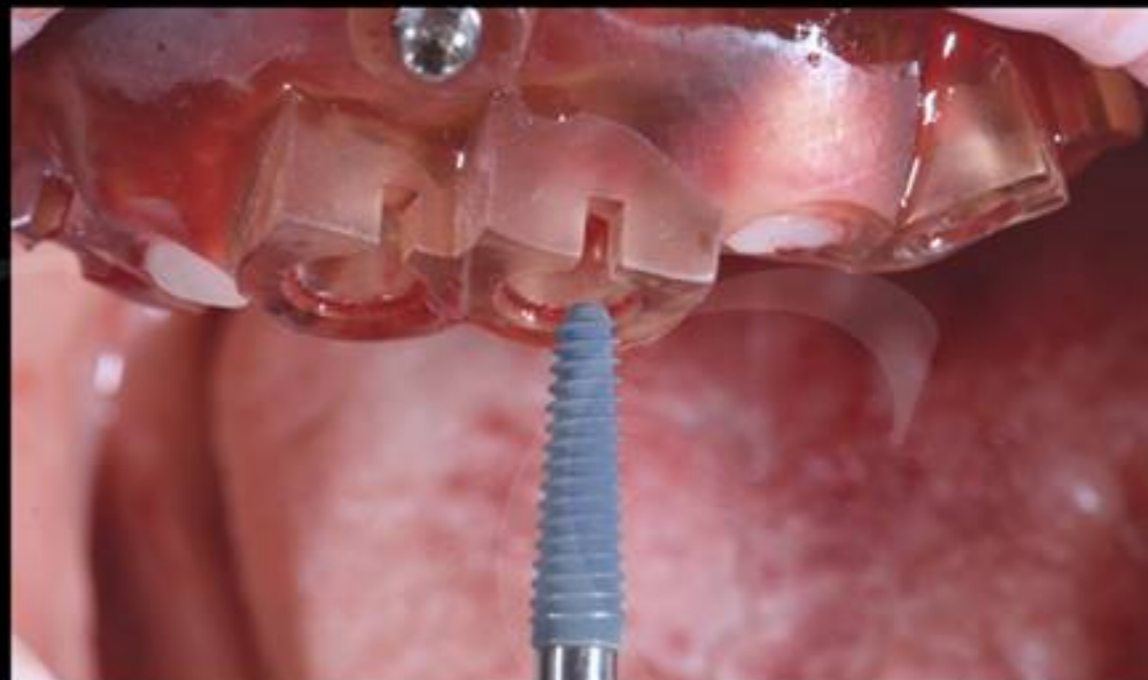
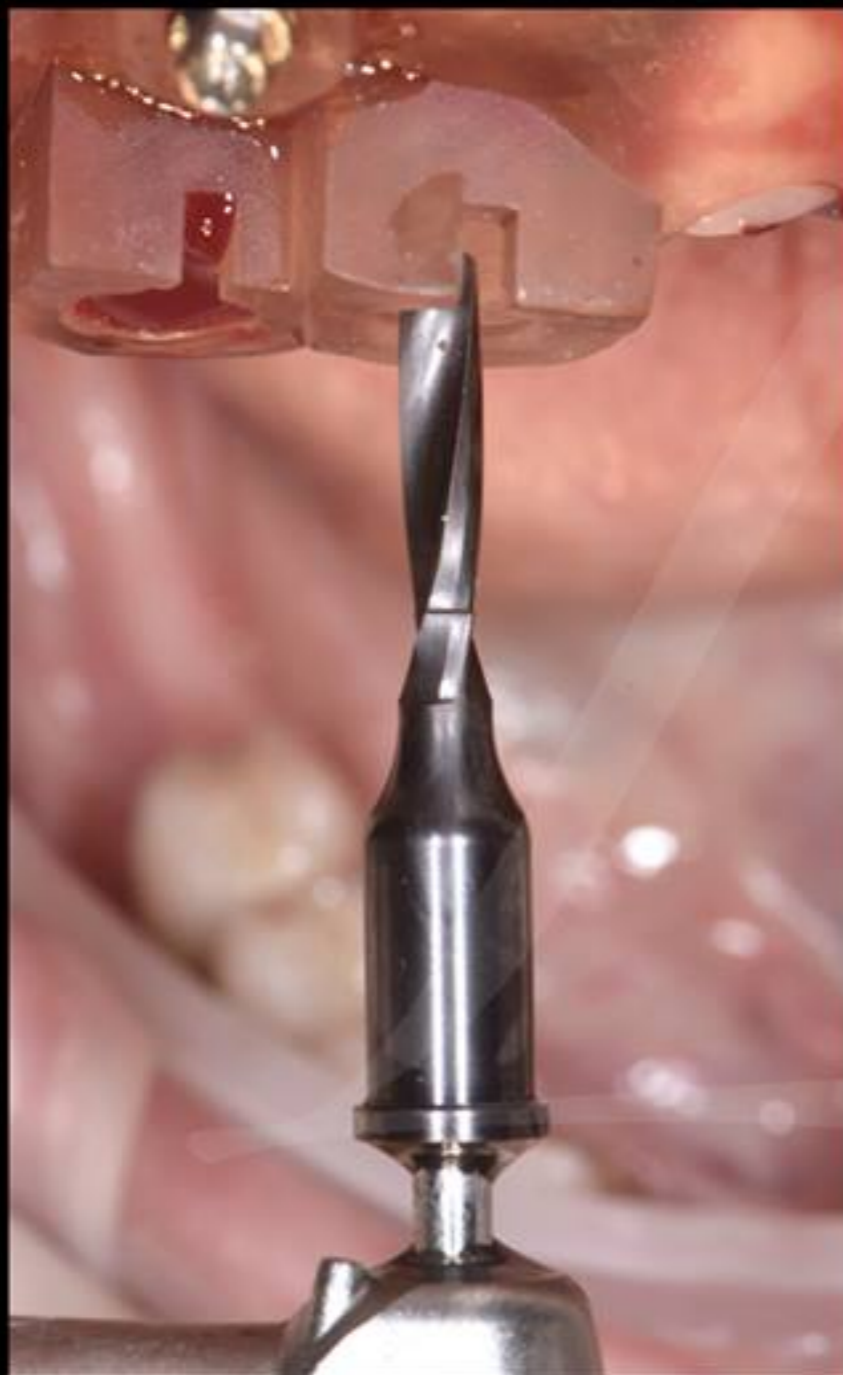
## Surgiguide dental and palatal mucosa support

Case by Dr. Laurent Sers

**Clinical Case:** R2GATE guided surgery

S  
u  
r  
g  
i  
c  
a  
l

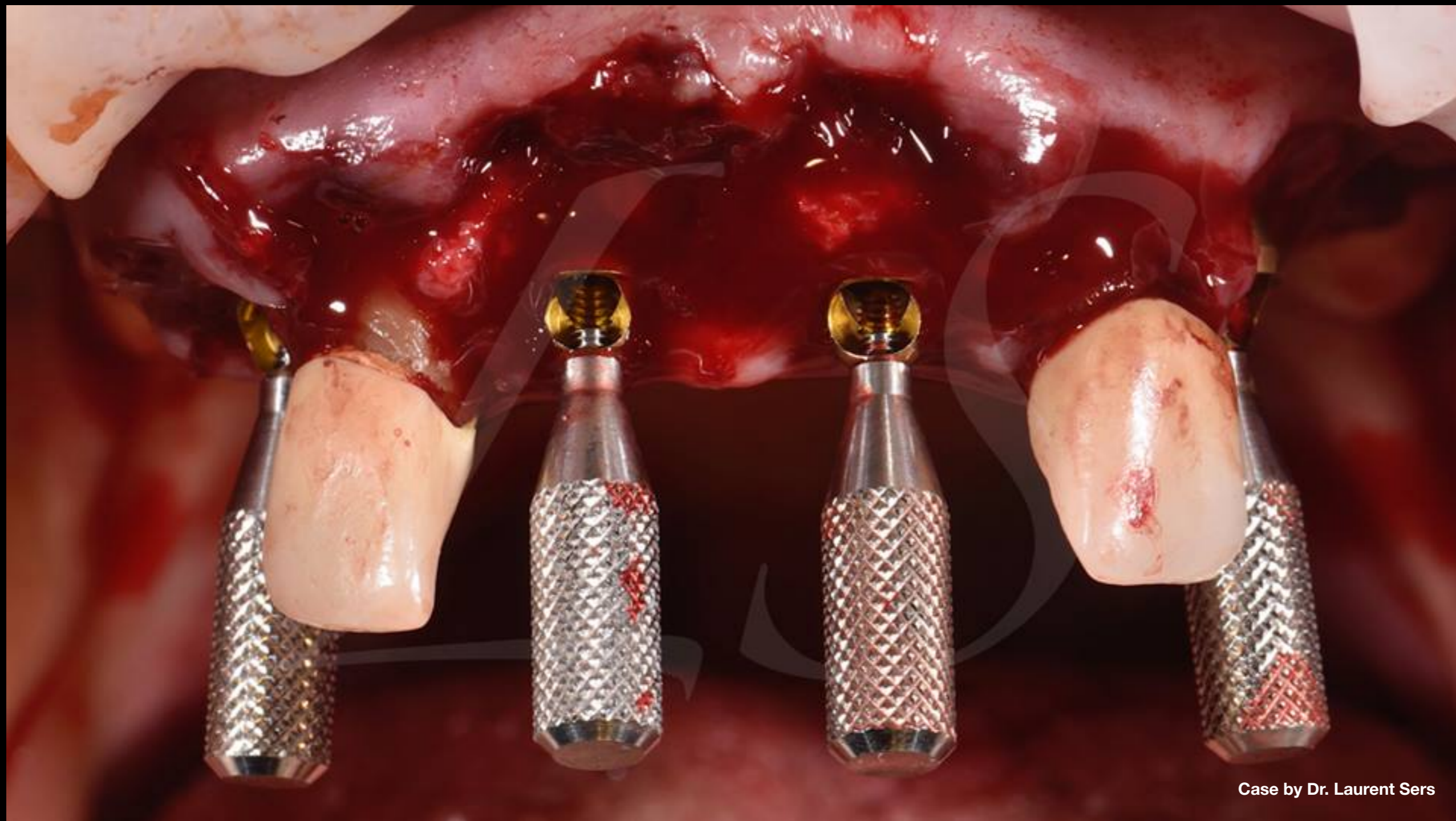


P  
r  
o  
t  
o  
c  
o  
l

Clinical Case: R2GATE guided surgery

Case by Dr. Laurent Sers

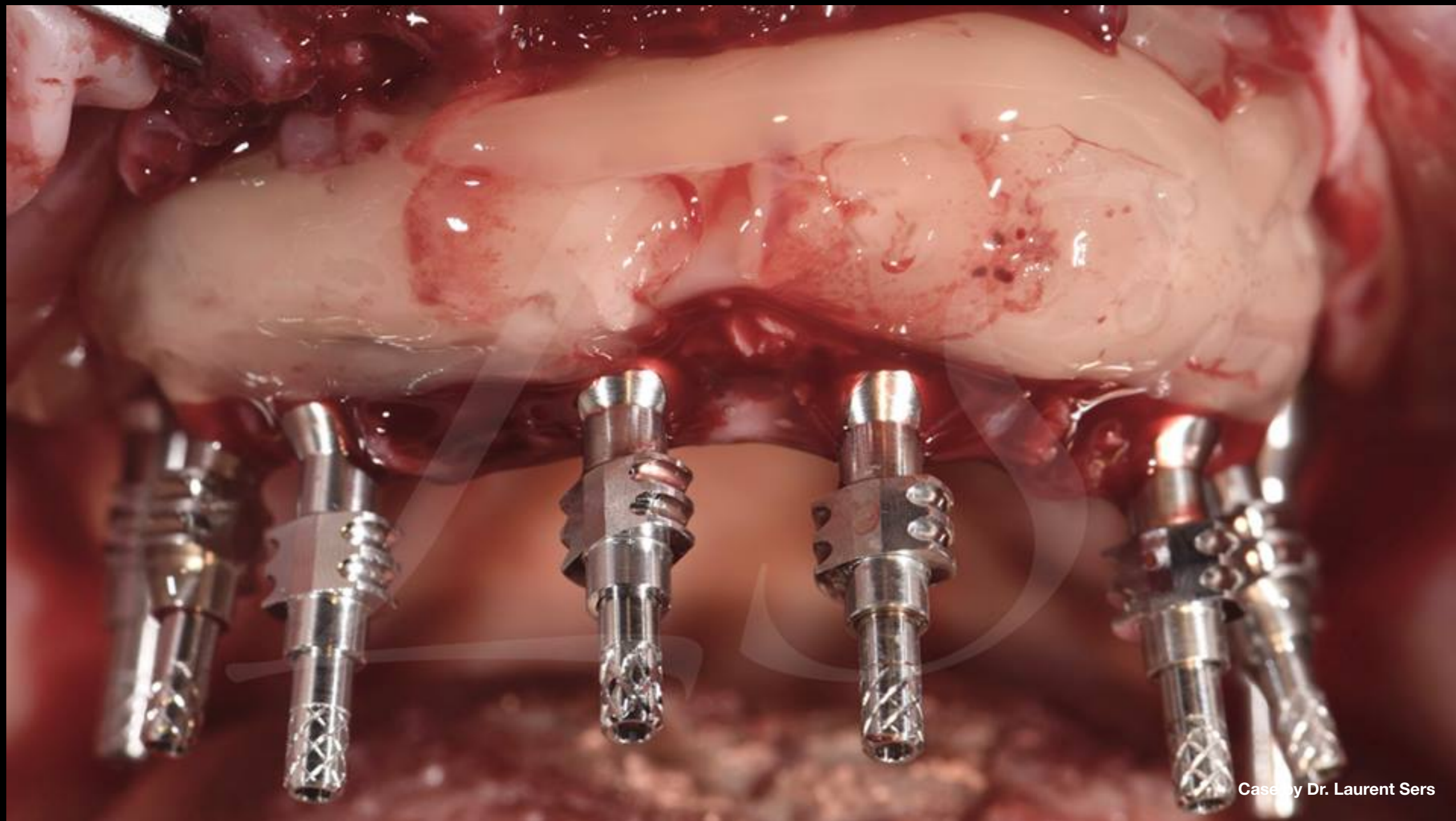




Case by Dr. Laurent Sers

Clinical Case

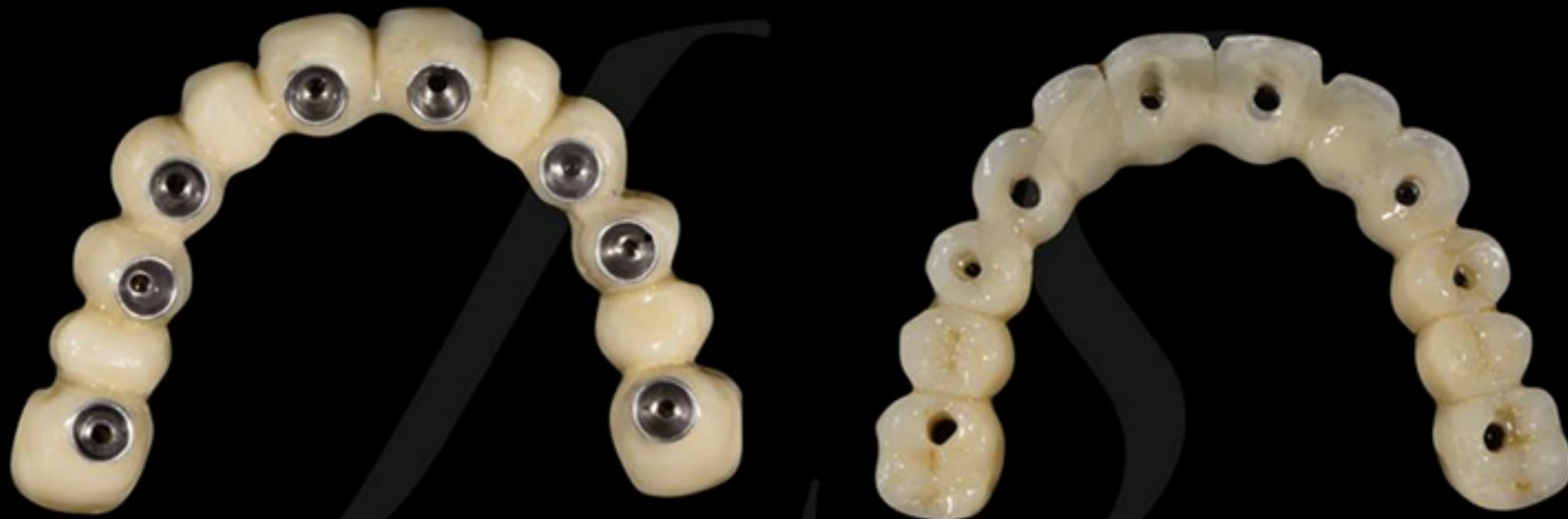



Case by Dr. Laurent Sers

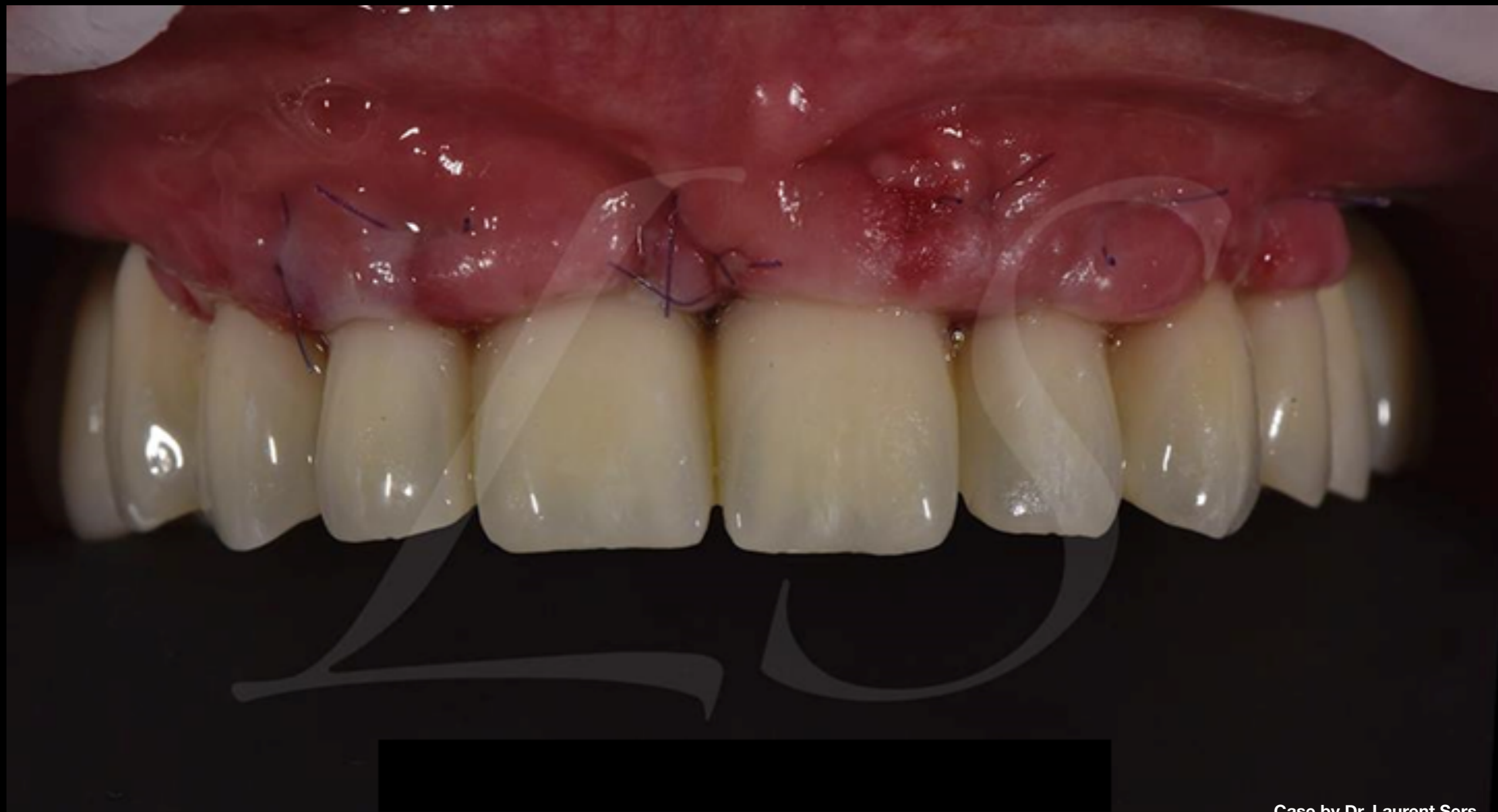## Clinical Case





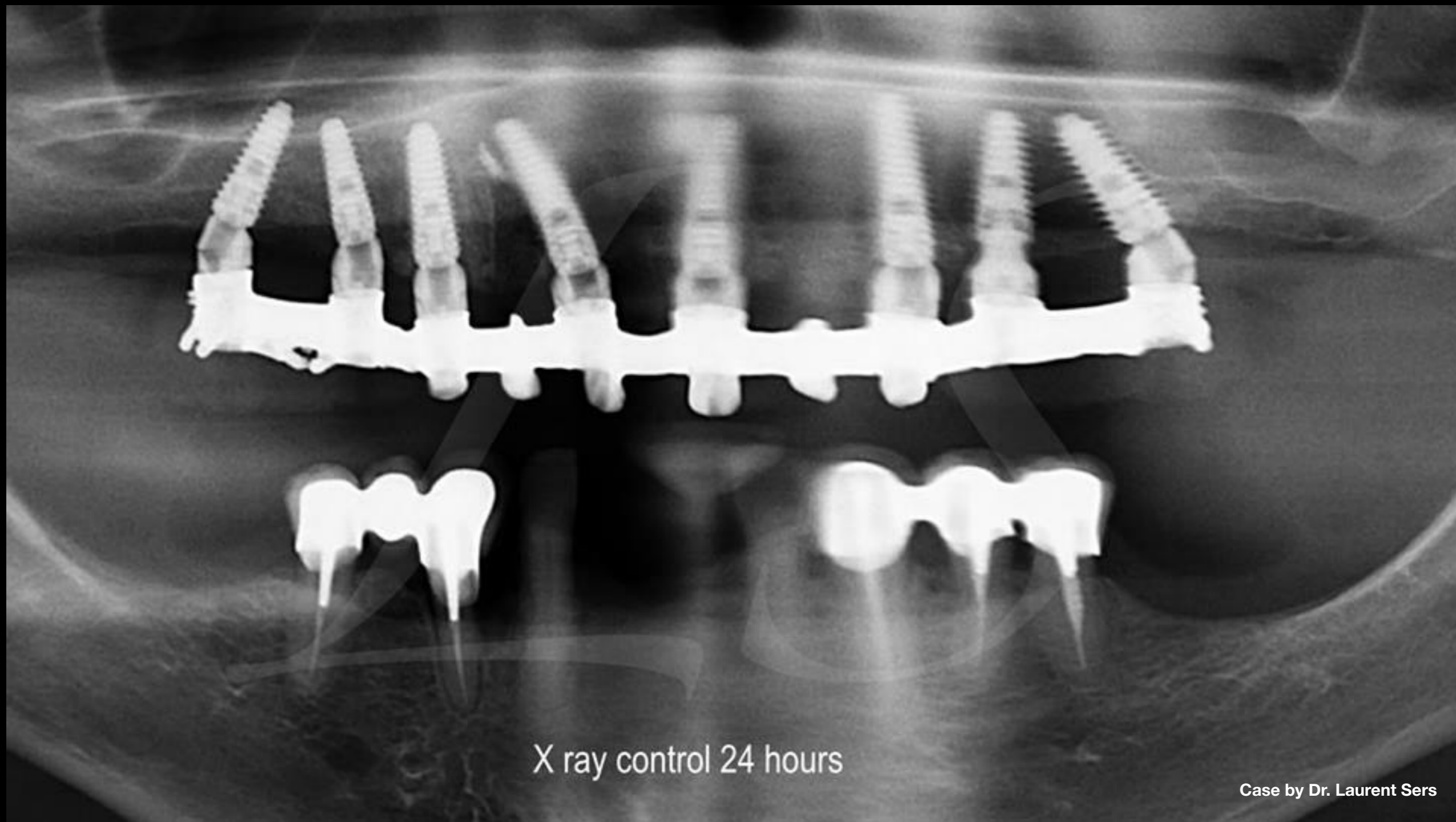
Case by Dr. Laurent Sers

**Clinical Case:** Prosthesis completed in one day (metal framework & composite)



Case by Dr. Laurent Sers

**Clinical Case:** Prosthesis placed 24hrs post surgery



X ray control 24 hours

Case by Dr. Laurent Sers

Clinical Case: X-ray control at 24hrs

