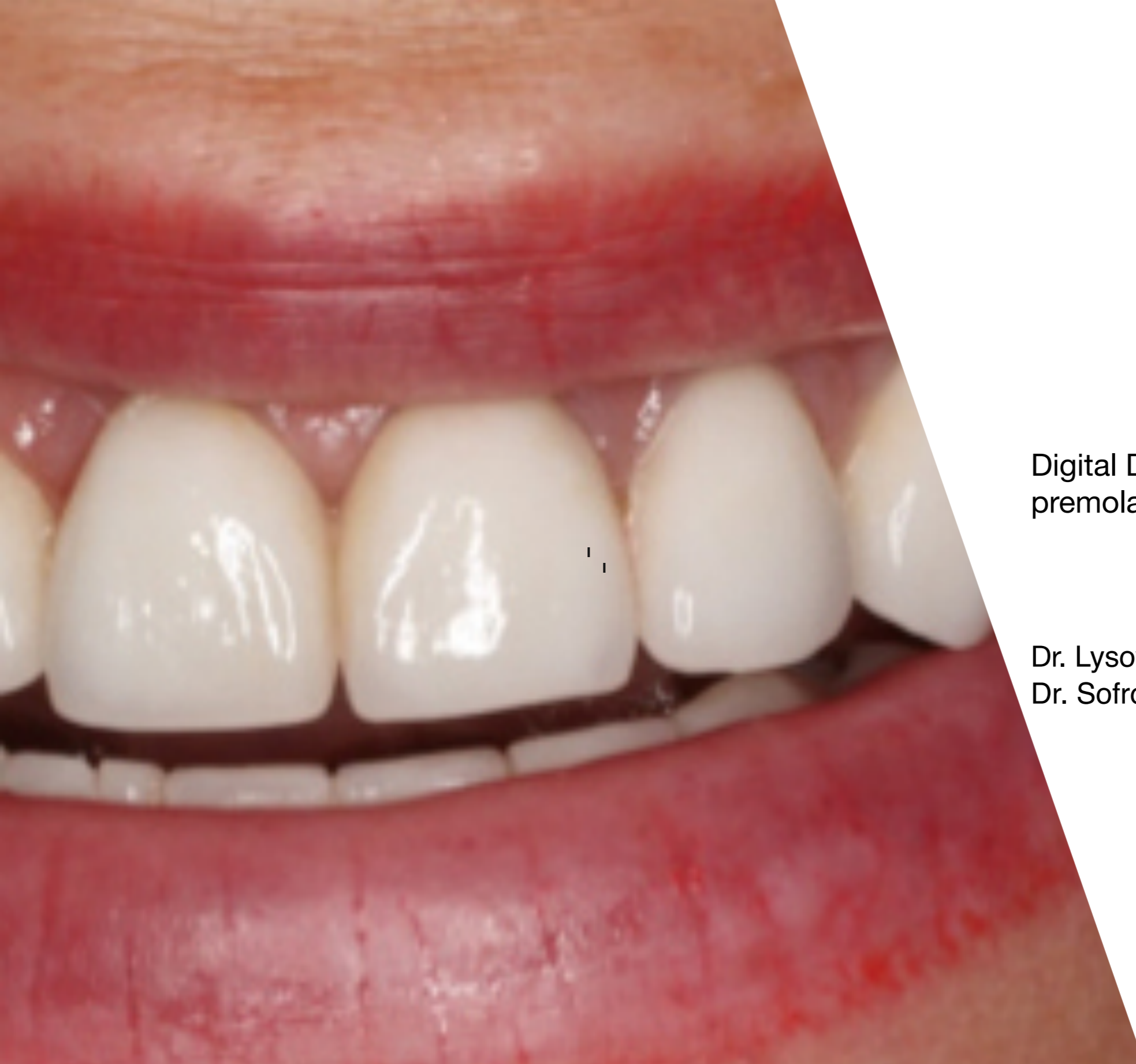
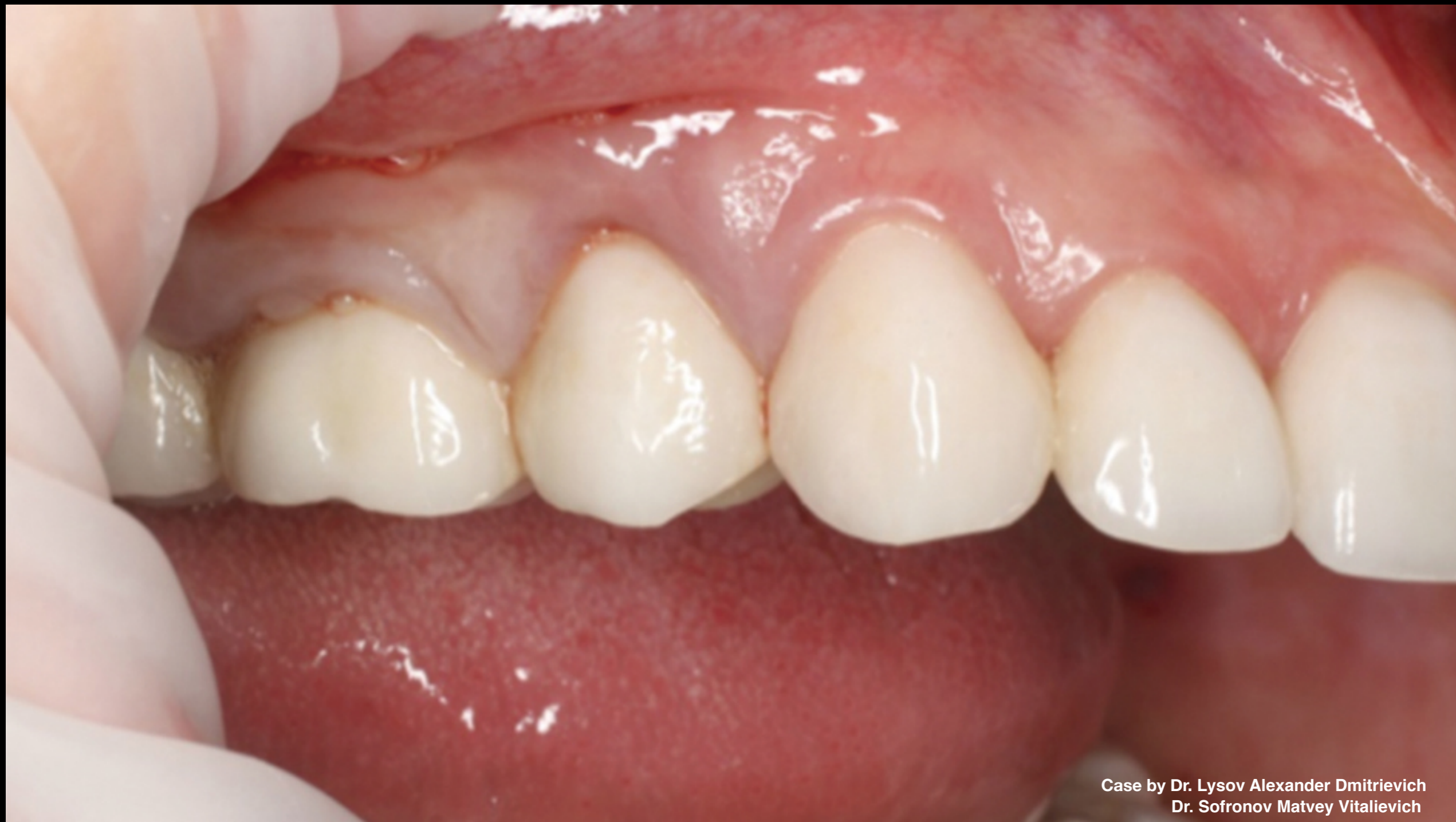


Digital Data Save concept in upper jaw
premolar area

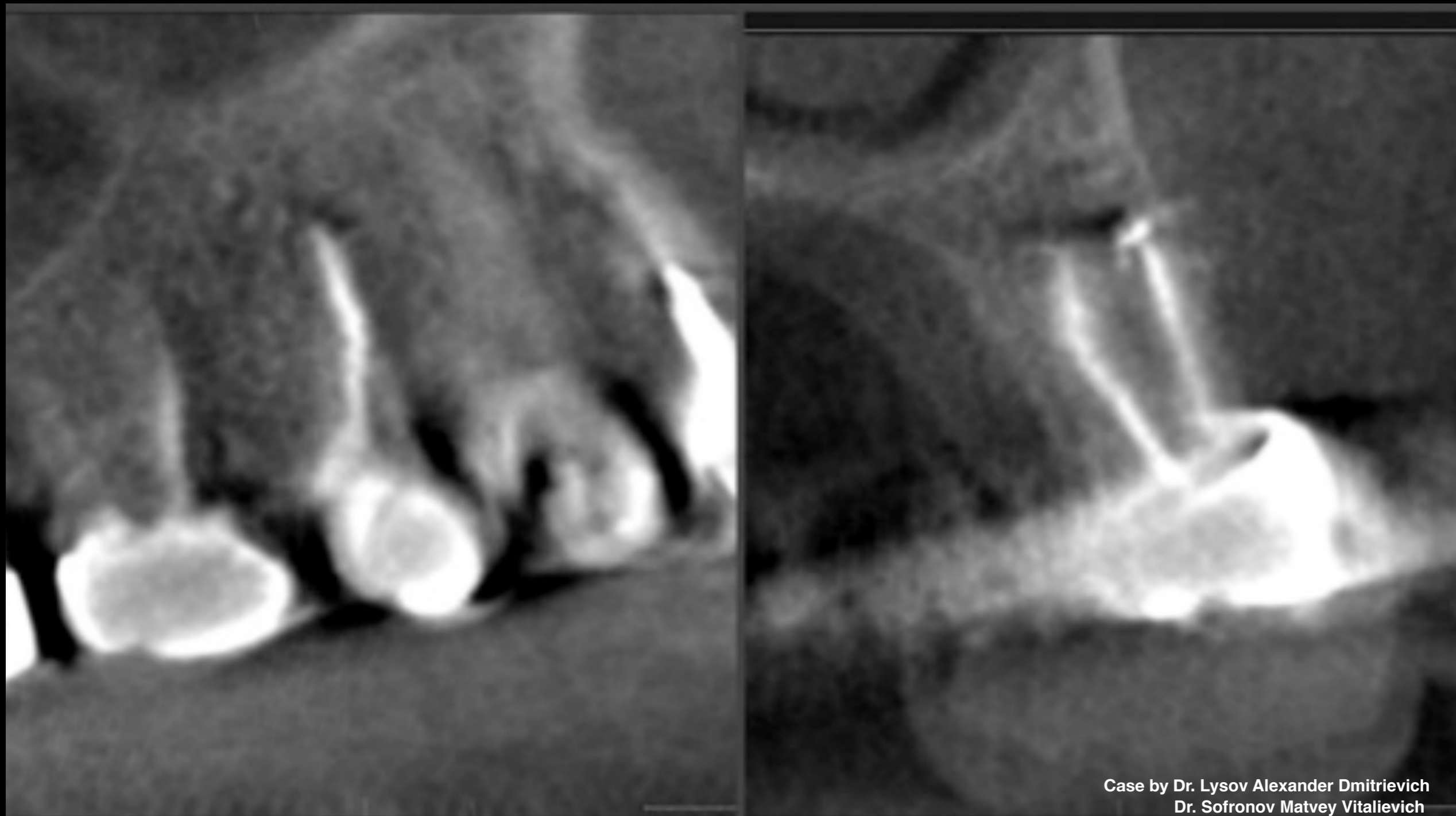Dr. Lysov Alexander Dmitrievich &
Dr. Sofronov Matvey Vitalievich



Case by Dr. Lysov Alexander Dmitrievich
Dr. Sofronov Matvey Vitalievich

Clinical Case:

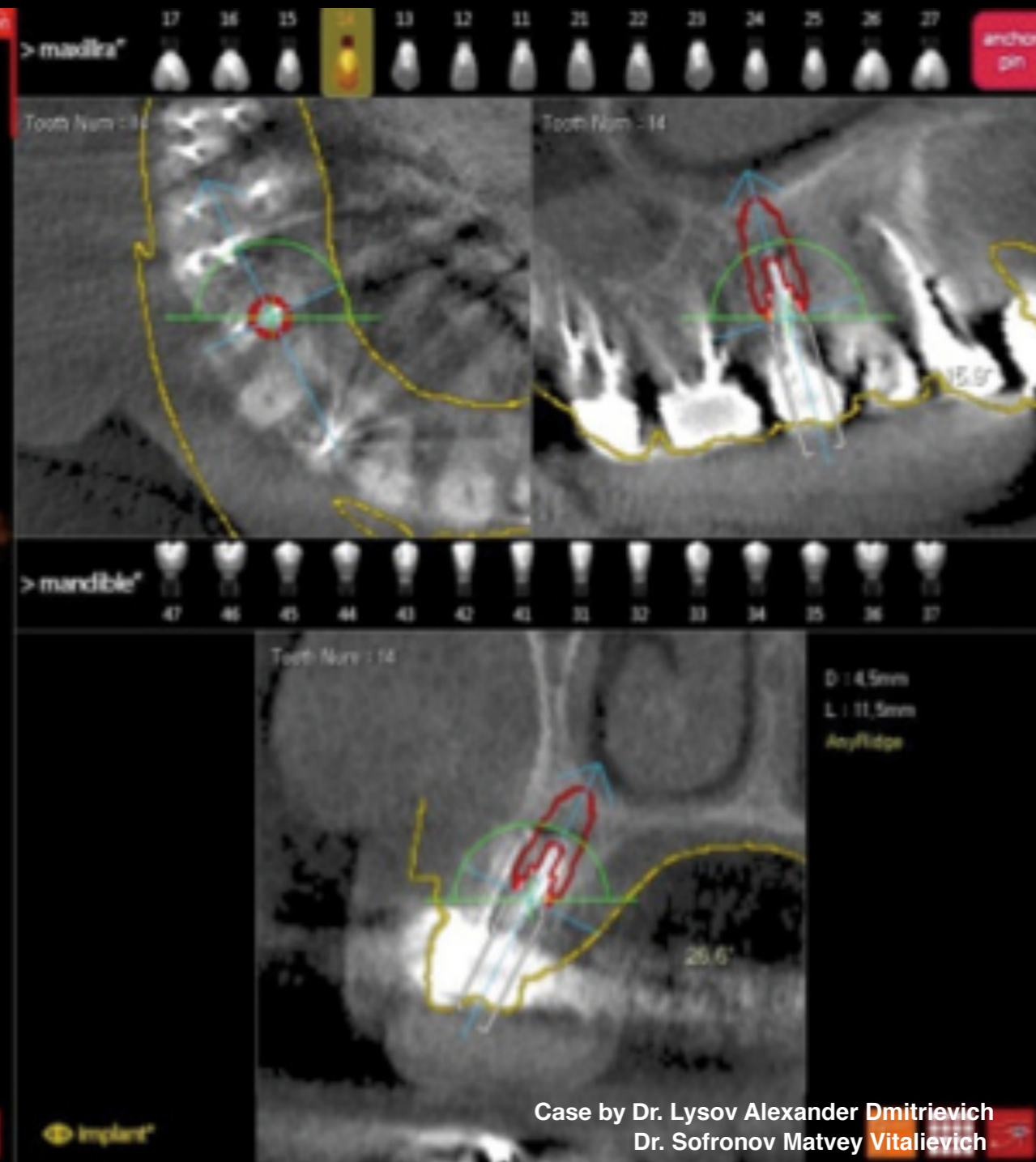
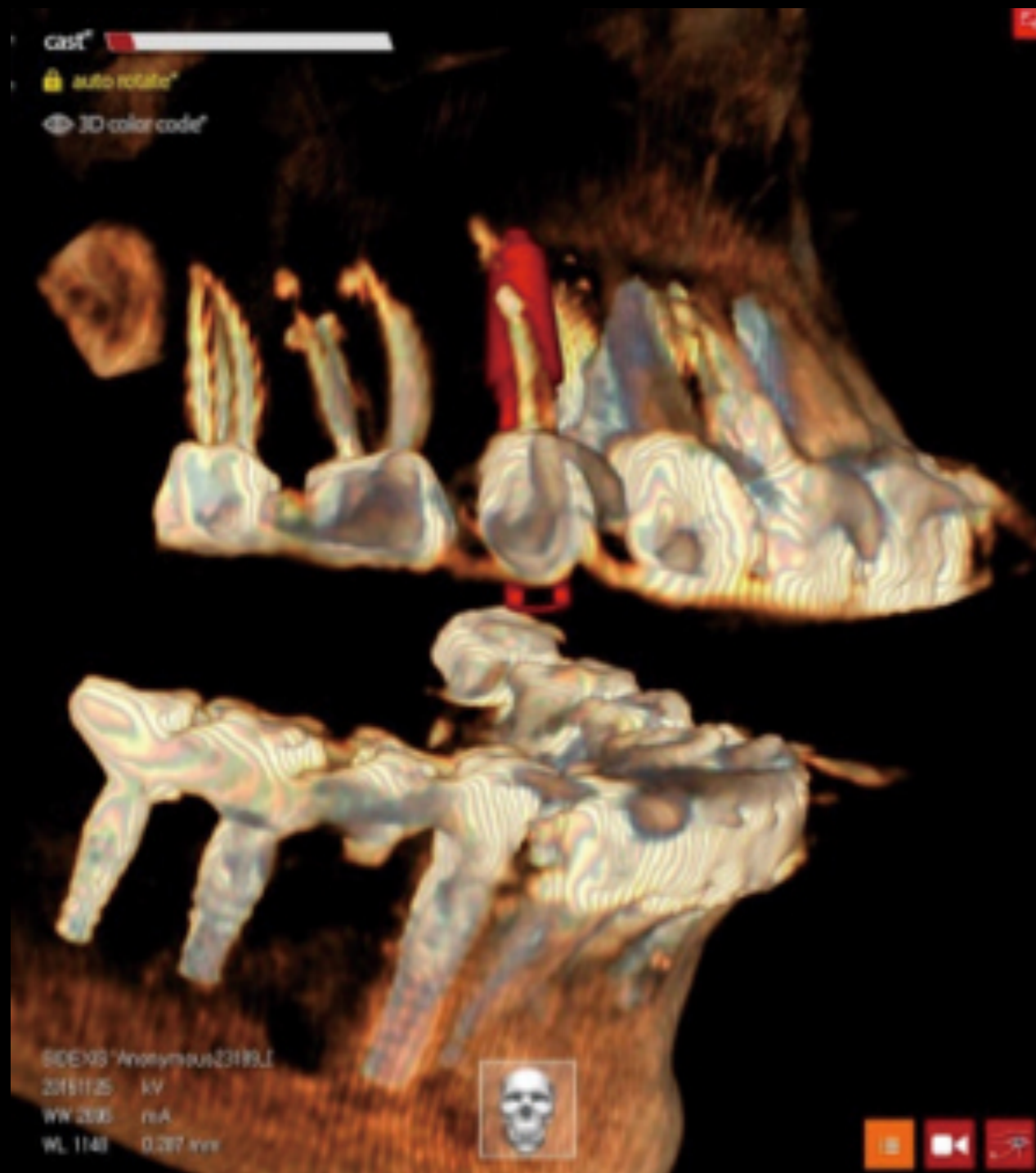- Patient presented with constant rasfixation of orthopedic crown & chewing pain related to tooth #14
- Percussion of tooth #14 was positive
- Examination revealed periodontal pocket at 6mm depth from medial surface



Case by Dr. Lysov Alexander Dmitrievich
Dr. Sofronov Matvey Vitalievich

Clinical Case:

- CBCT revealed destruction of bone tissue at apex of tooth #14
- Diagnosis was exacerbation of chronic periodontitis of tooth #14 & absence of ferul-effect at tooth #14
- Patient requested immediate restoration with reliable & highly-aesthetic results

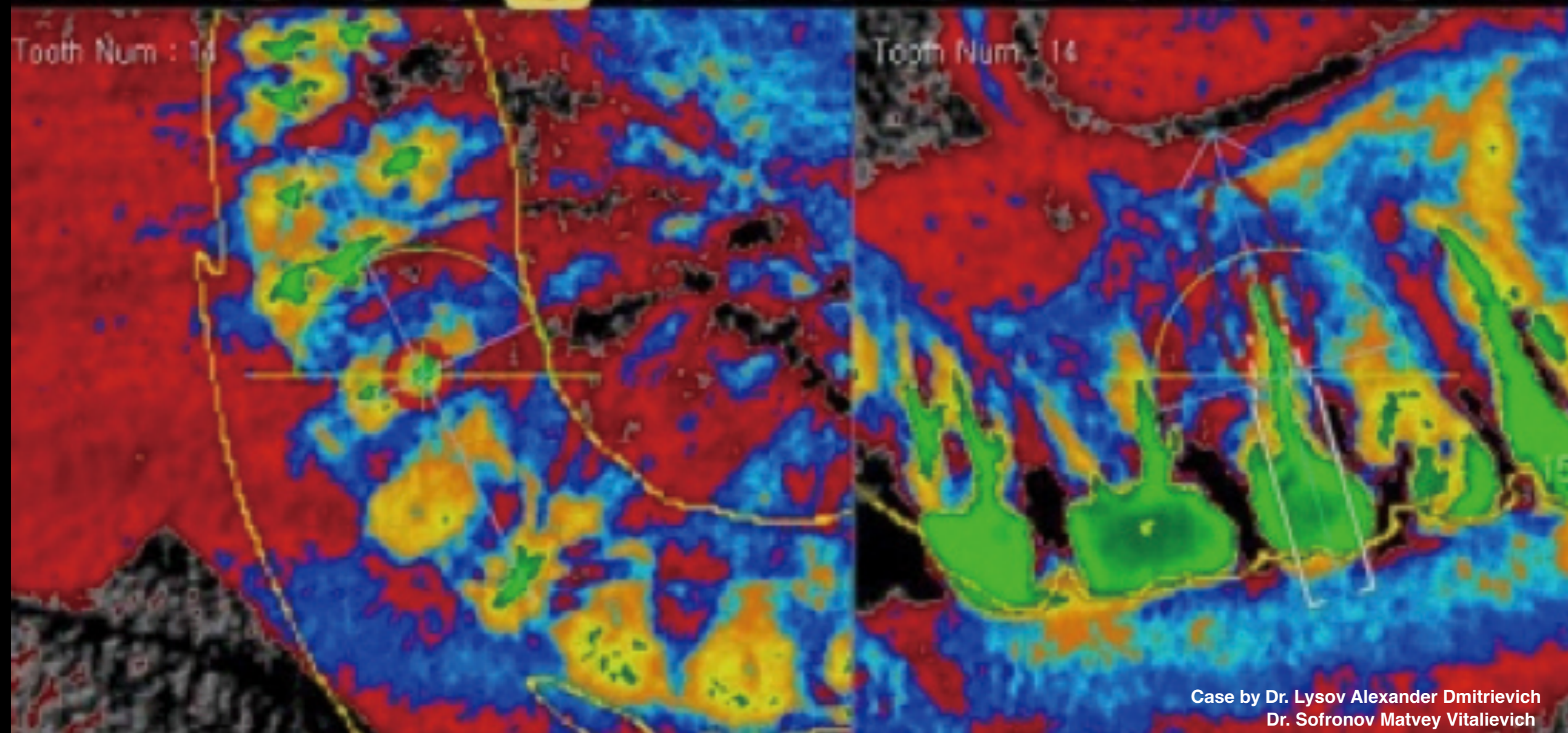


Case by Dr. Lysov Alexander Dmitrievich
Dr. Sofronov Matvey Vitalievich

Clinical Case:

- Preparation protocol for implant installation
- Immediate placement of AnyRidge implant using R2GATE planning & surgical guide

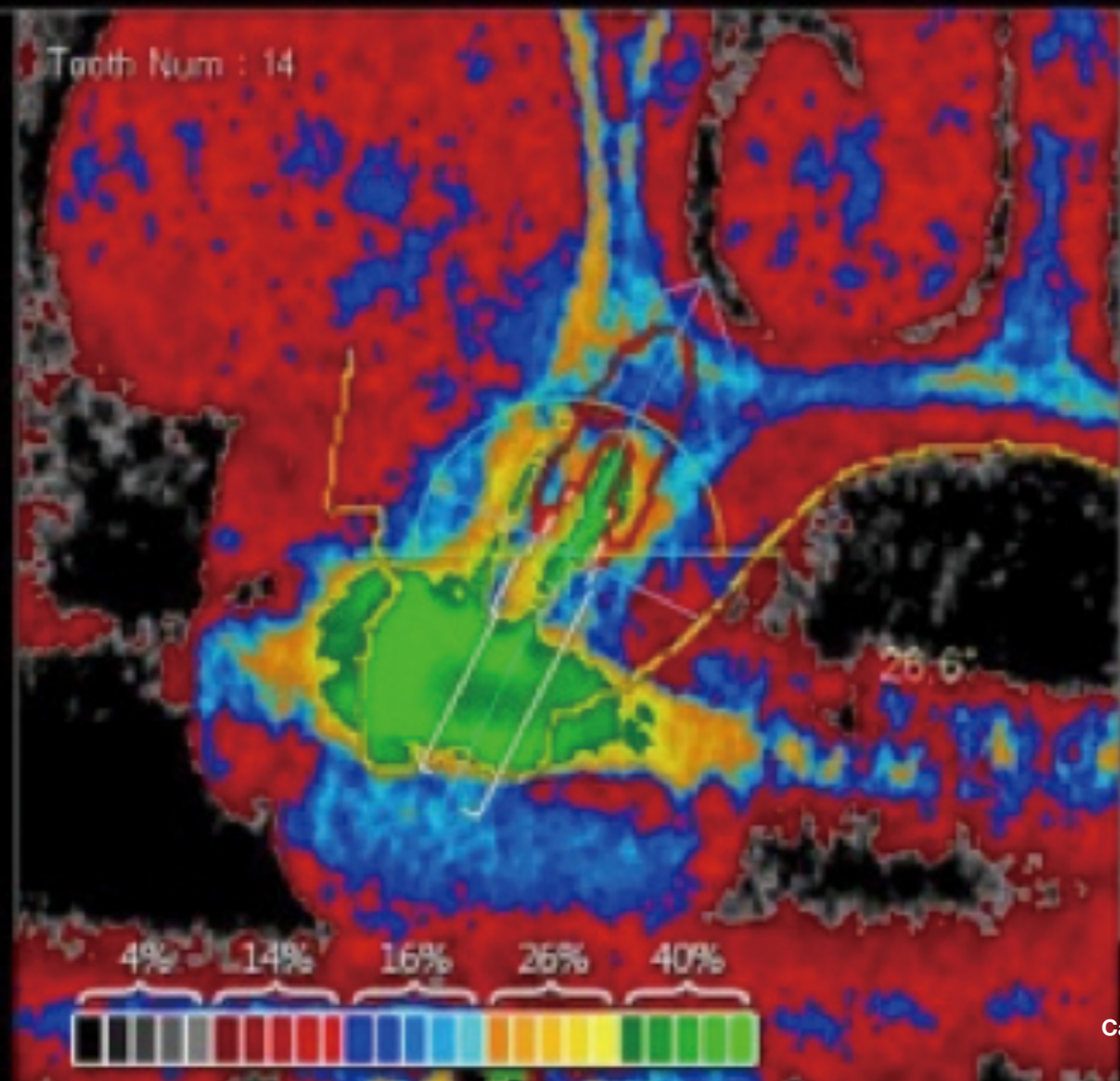




Case by Dr. Lysov Alexander Dmitrievich
Dr. Sofronov Matvey Vitalievich

Clinical Case: Digital Eye function revealing density of bone tissue

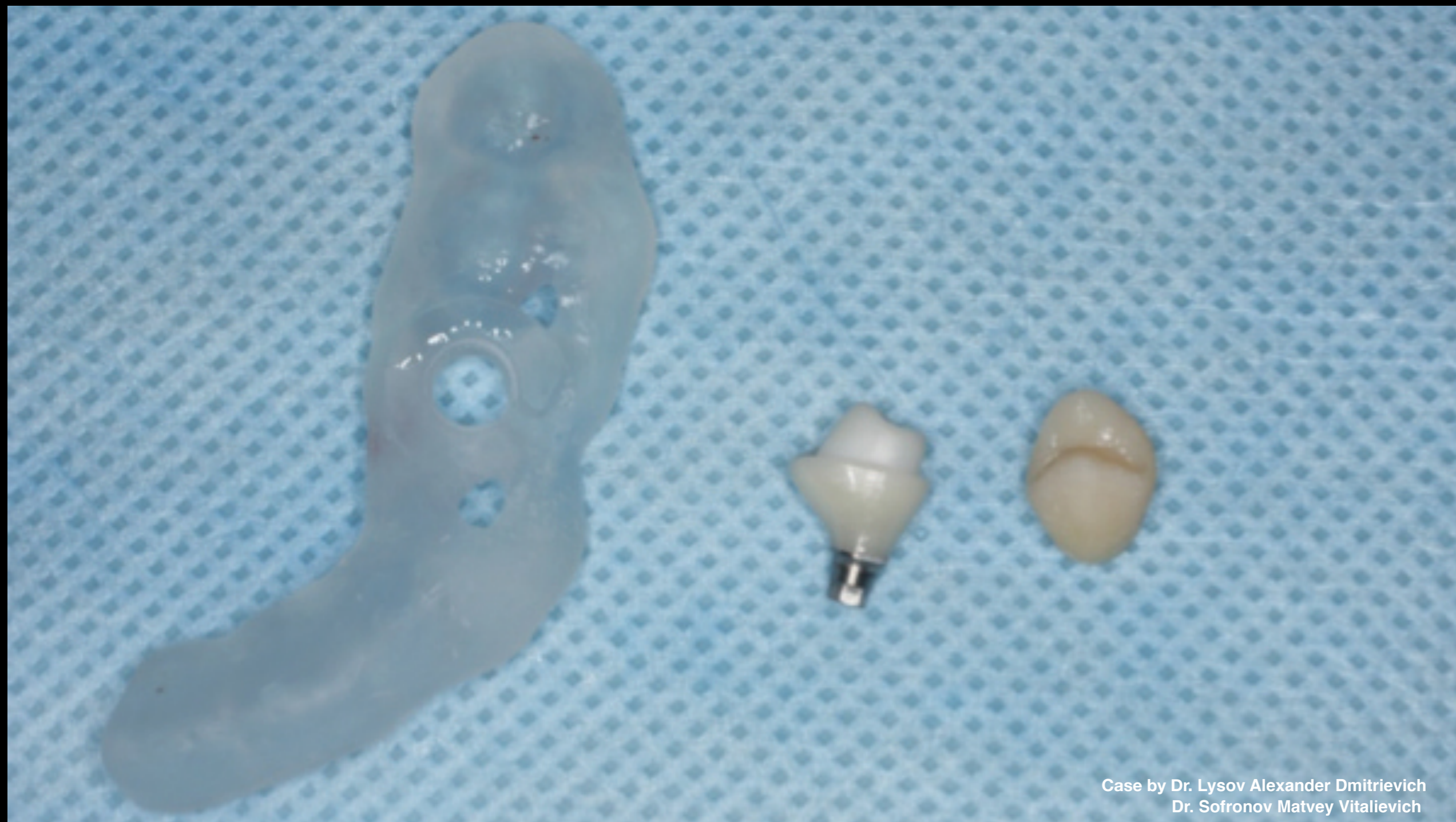



Case by Dr. Lysov Alexander Dmitrievich
Dr. Sofronov Matvey Vitalievich

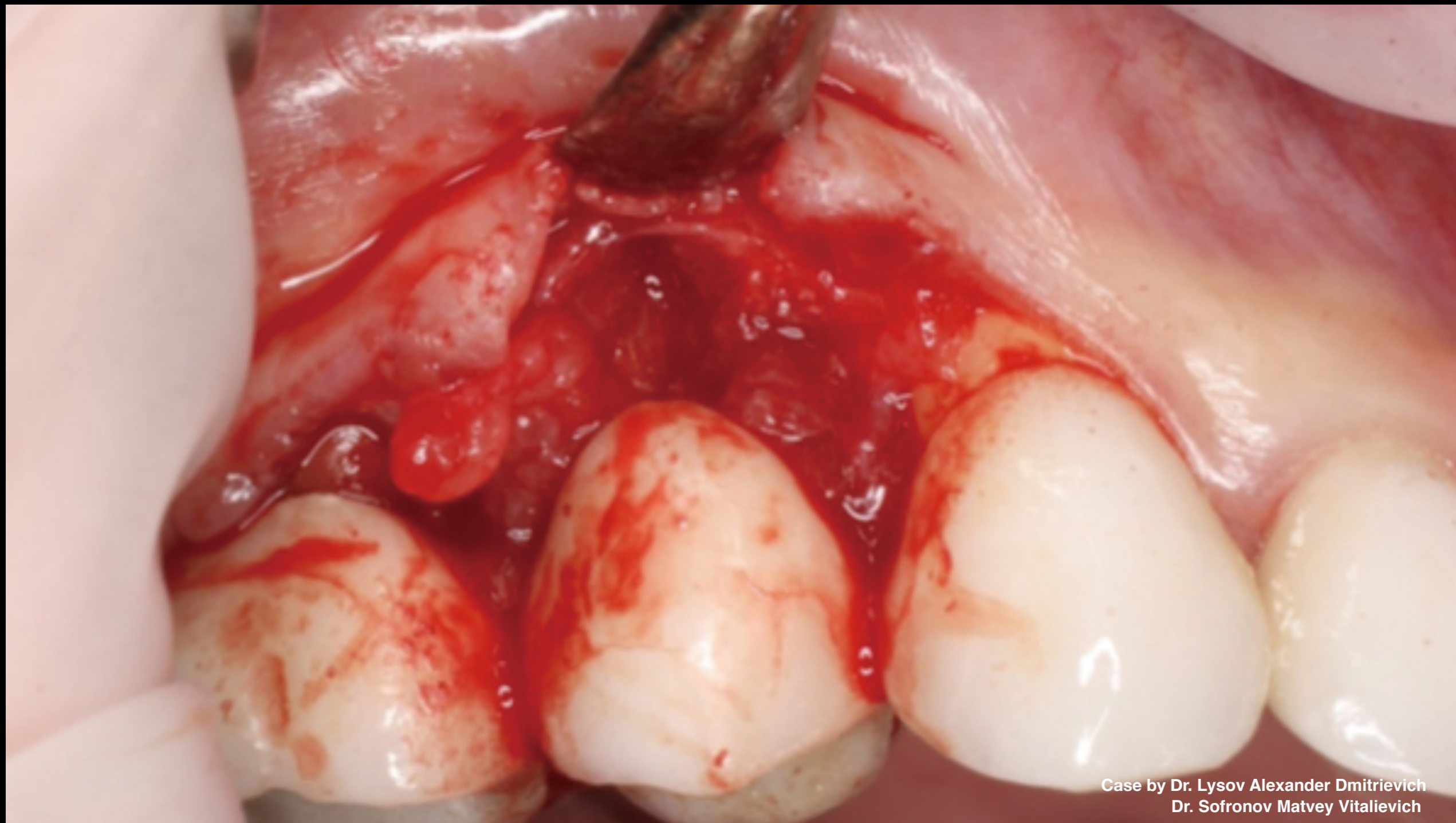Clinical Case: Digital Eye function revealing density of bone tissue





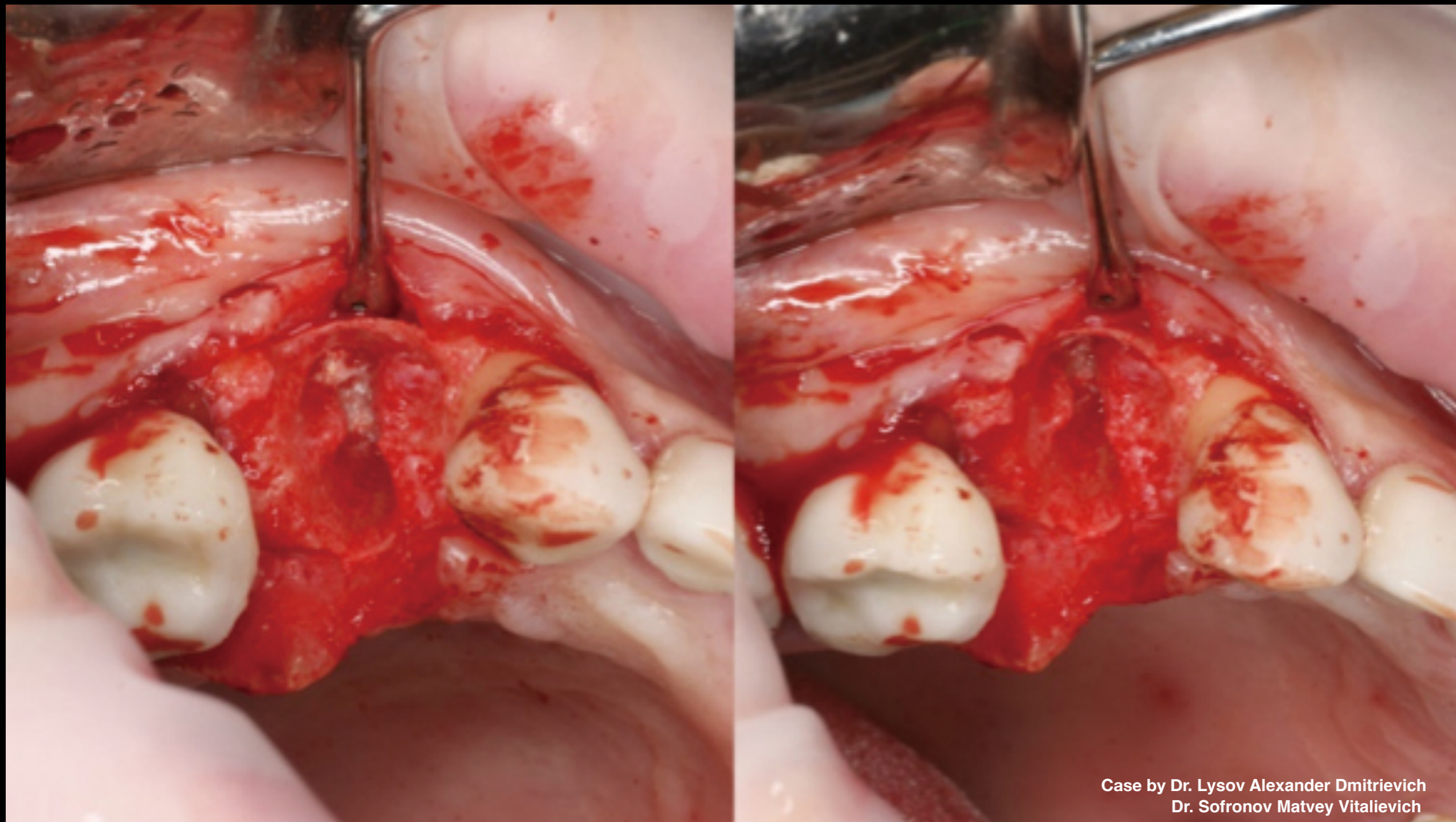
Case by Dr. Lysov Alexander Dmitrievich
Dr. Sofronov Matvey Vitalievich

Clinical Case: R2GATE Guide, permanent customized zirconium abutment, & temporary CAD/CAM crown



Case by Dr. Lysov Alexander Dmitrievich
Dr. Sofronov Matvey Vitalievich

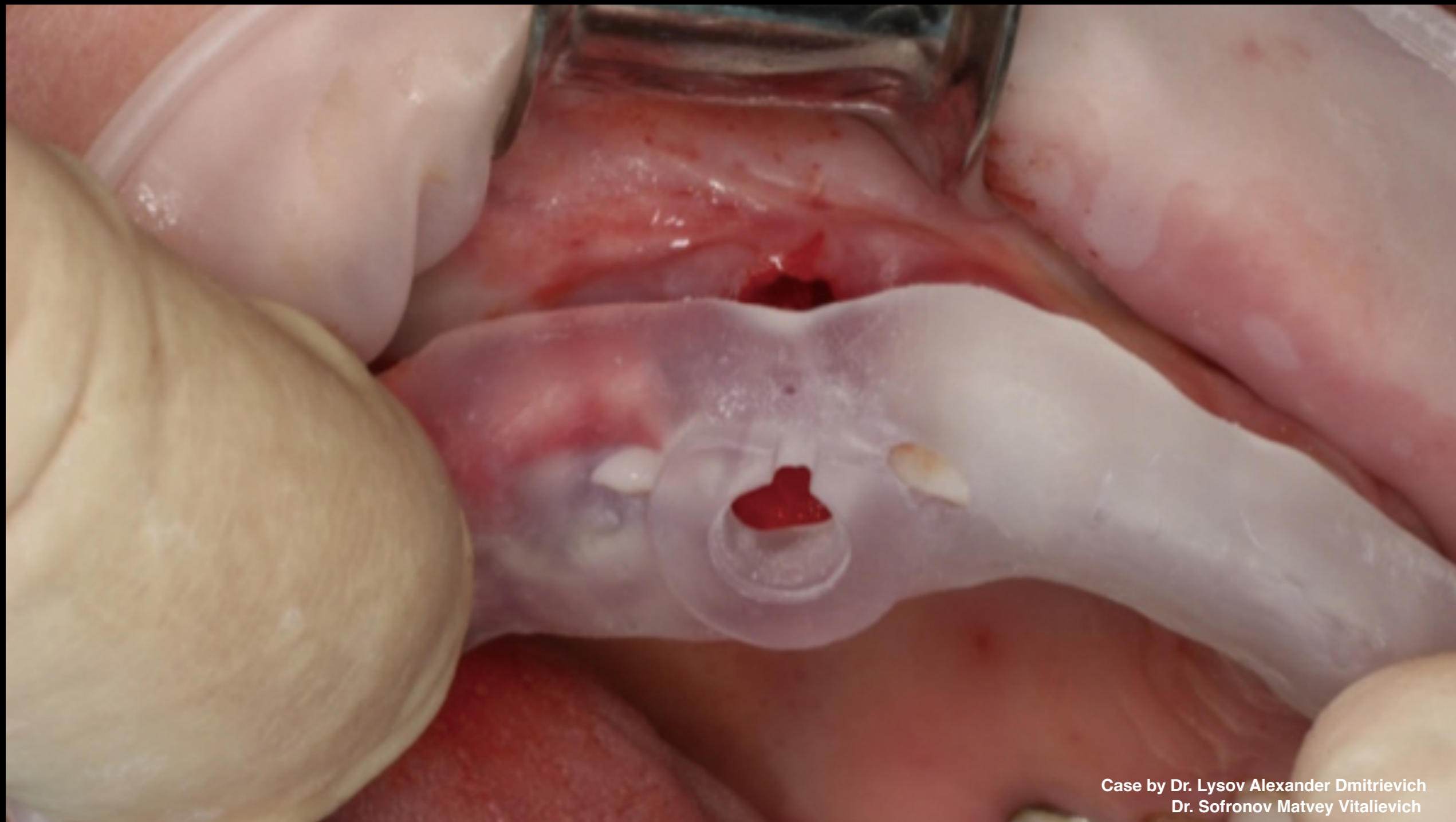
Clinical Case: When flap was peeled off in region of tooth #14, growth of granulation tissue was found on entire surface of orthopedic structure



Case by Dr. Lysov Alexander Dmitrievich
Dr. Sofronov Matvey Vitalievich

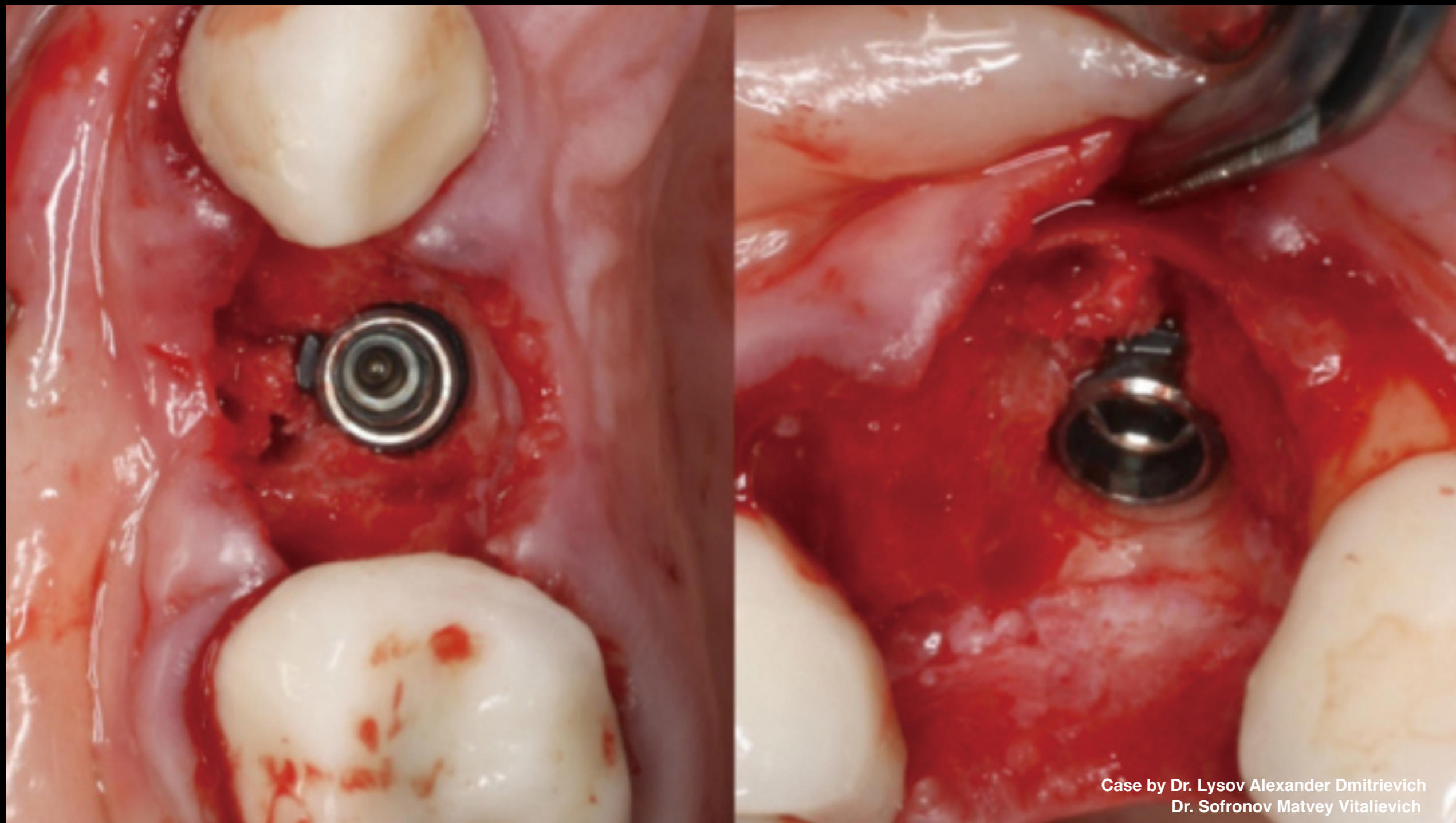
Clinical Case:

- Non-traumatic removal of tooth #14
- Demonstration of bone effect



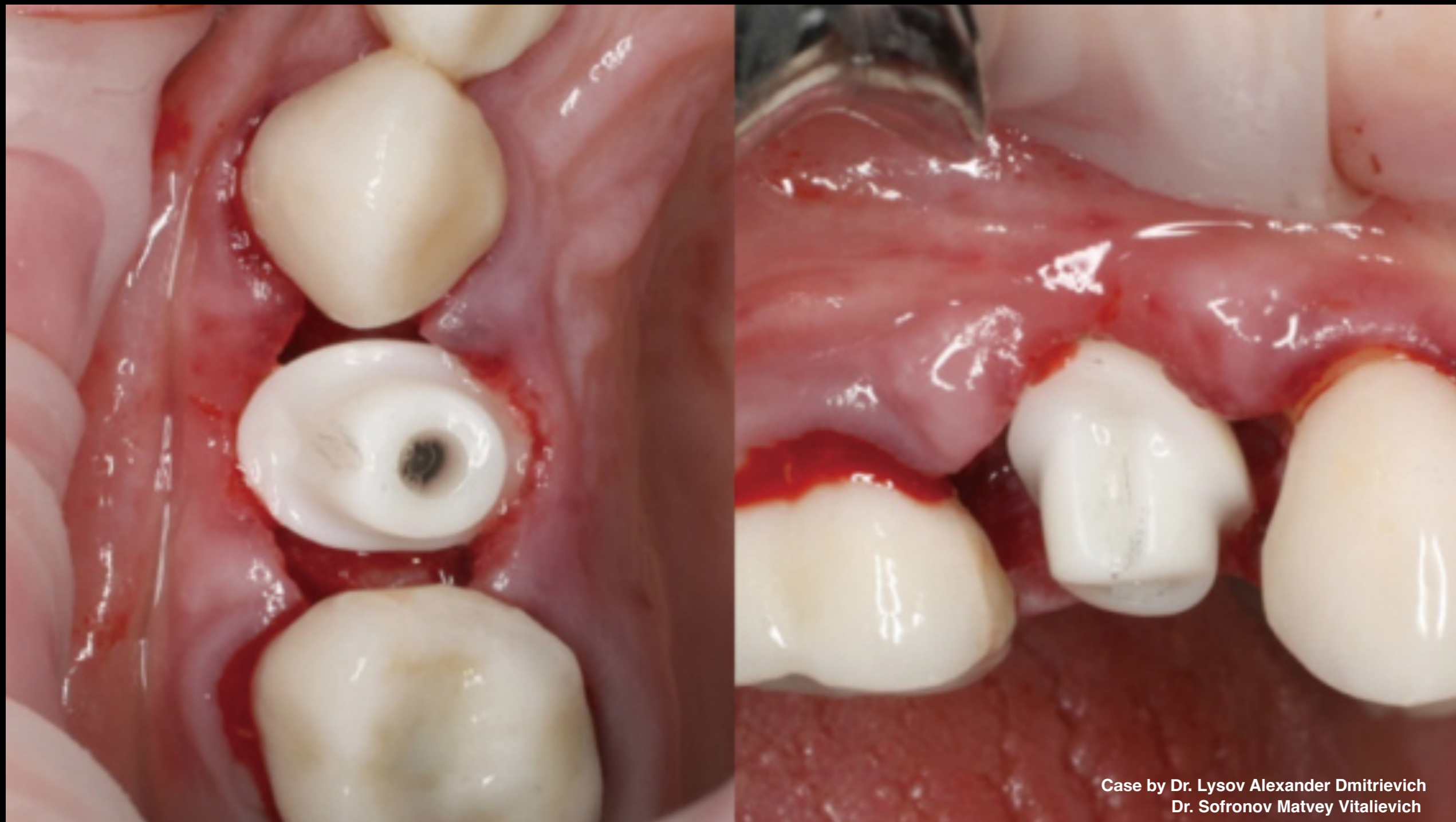
Case by Dr. Lysov Alexander Dmitrievich
Dr. Sofronov Matvey Vitalievich

Clinical Case: R2GATE surgical guide for accuracy



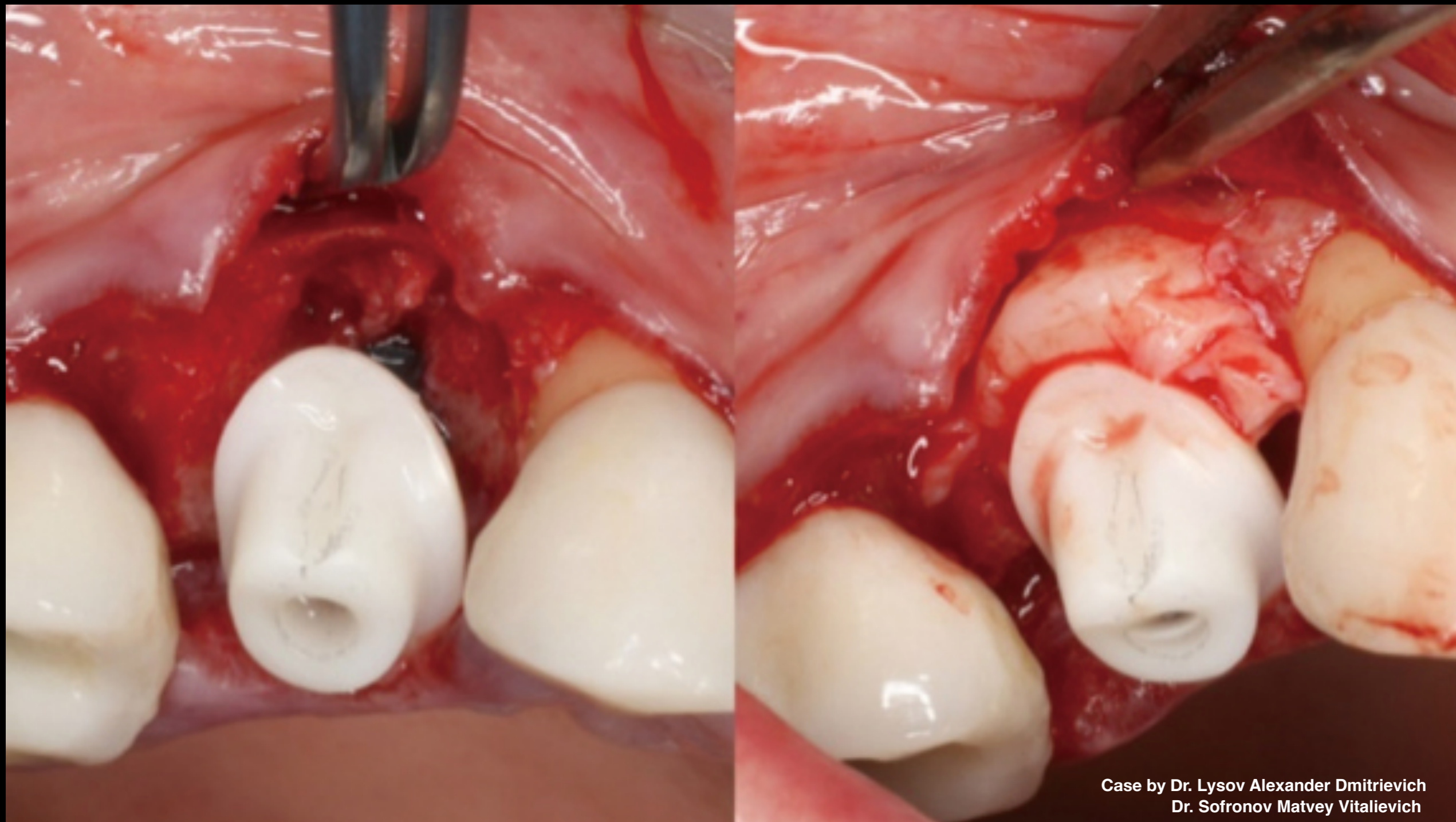Case by Dr. Lysov Alexander Dmitrievich
Dr. Sofronov Matvey Vitalievich

Clinical Case: Installed AnyRidge implant



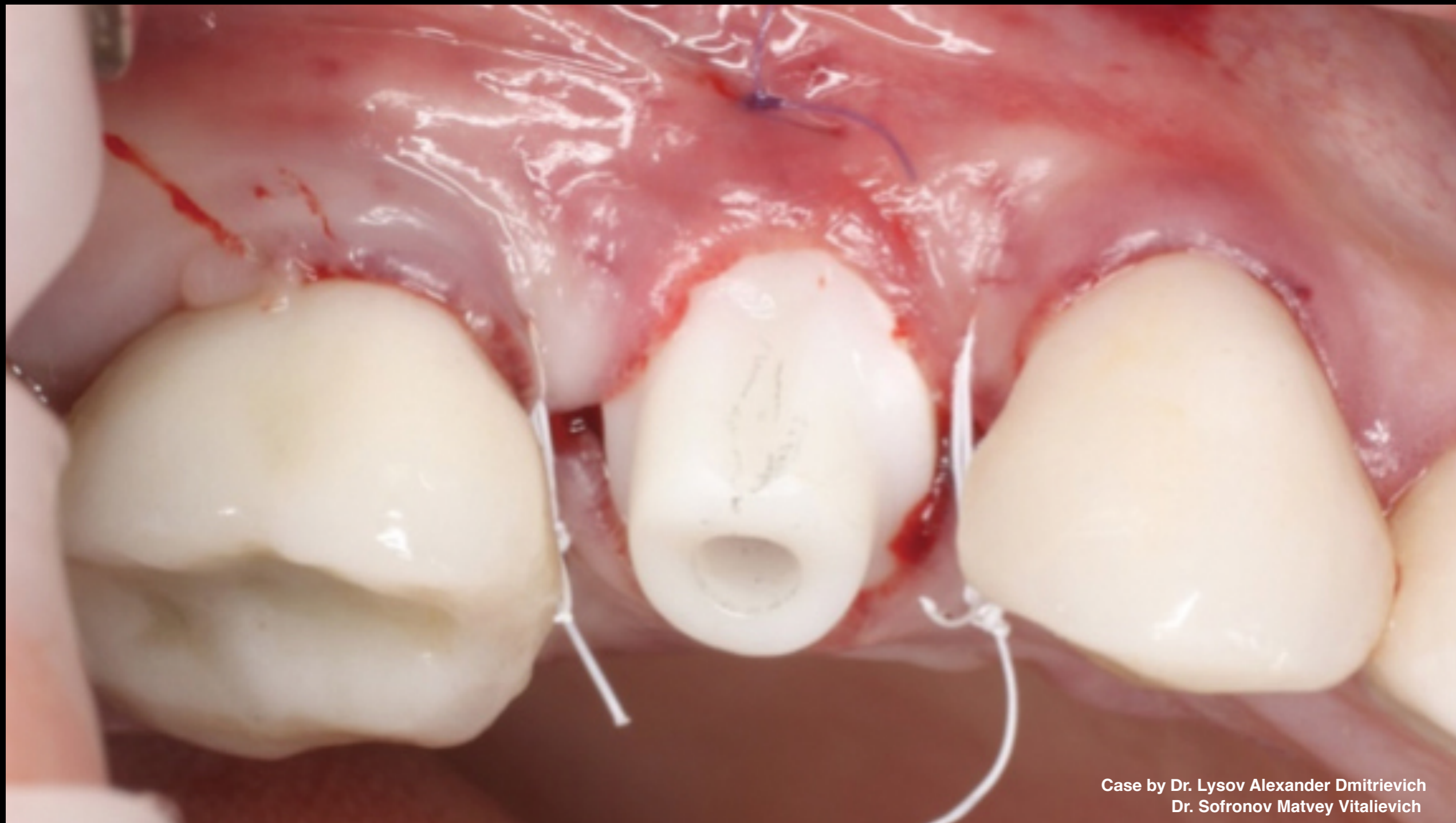Case by Dr. Lysov Alexander Dmitrievich
Dr. Sofronov Matvey Vitalievich

Clinical Case: Installed permanent customized zirconium abutment



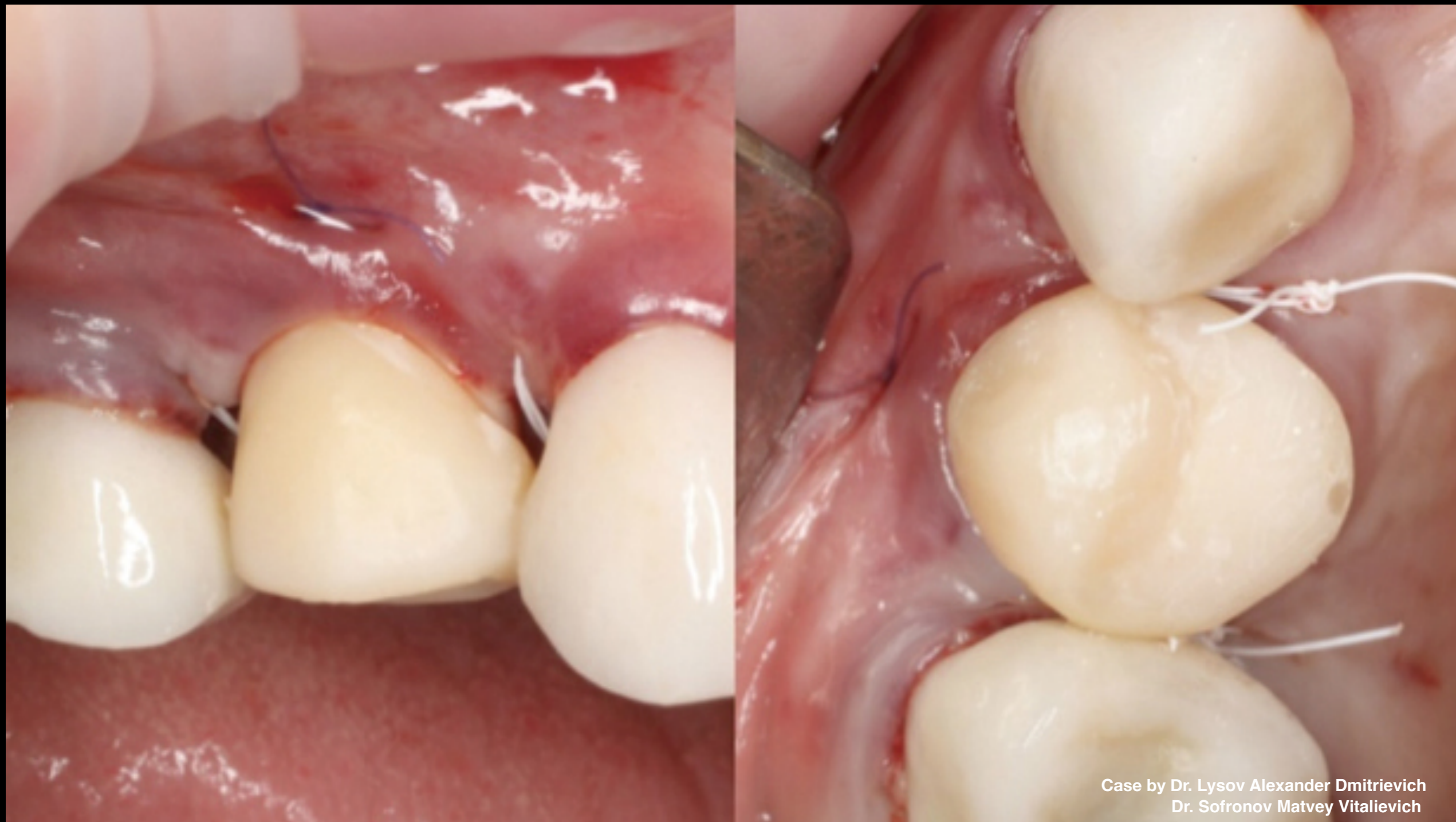Case by Dr. Lysov Alexander Dmitrievich
Dr. Sofronov Matvey Vitalievich

Clinical Case: As defect was seen on vestibular side, soft tissue augmentation was used to create conditions for formation of buffer zone in coronal direction



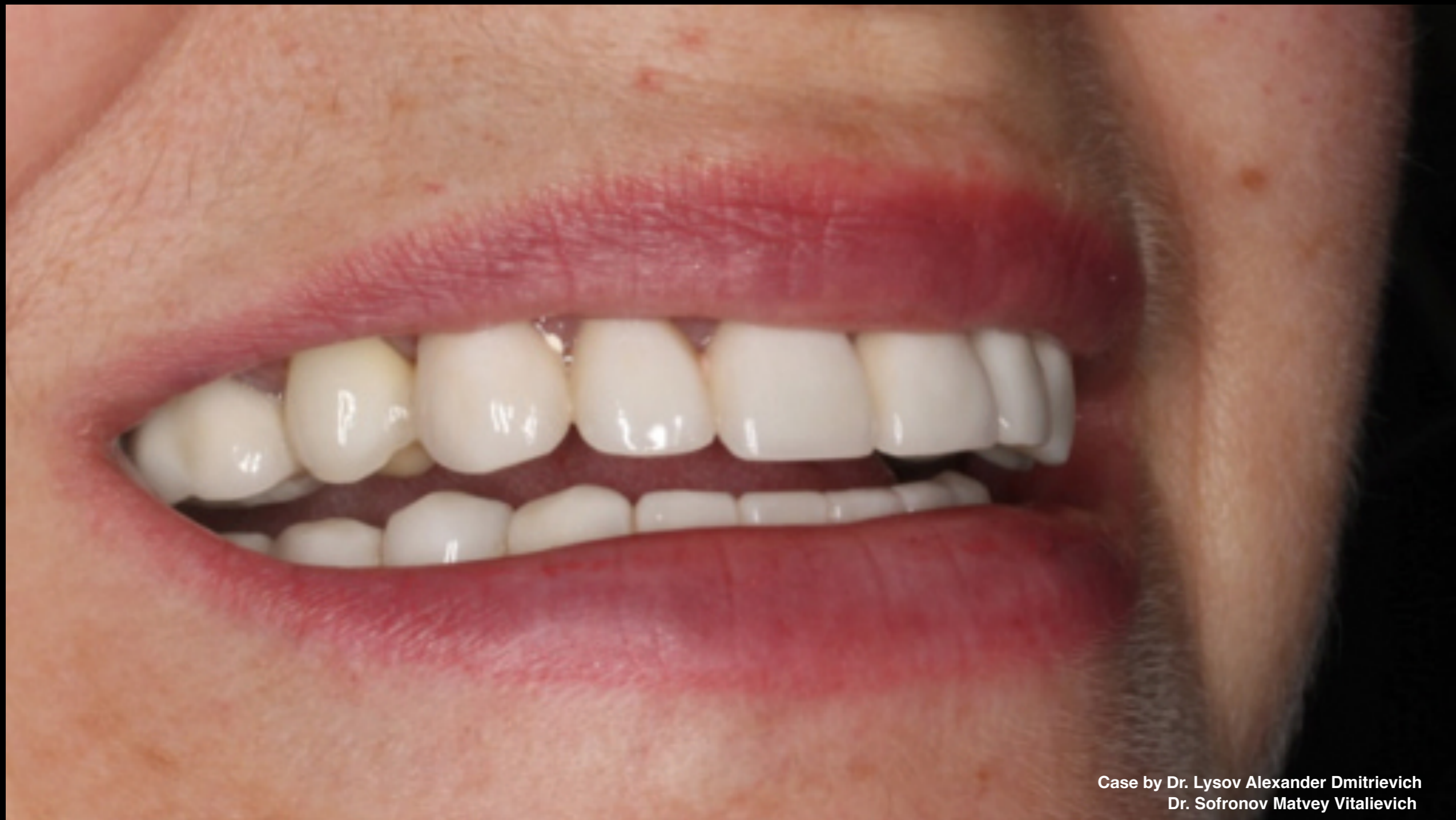Case by Dr. Lysov Alexander Dmitrievich
Dr. Sofronov Matvey Vitalievich

Clinical Case: Stitching



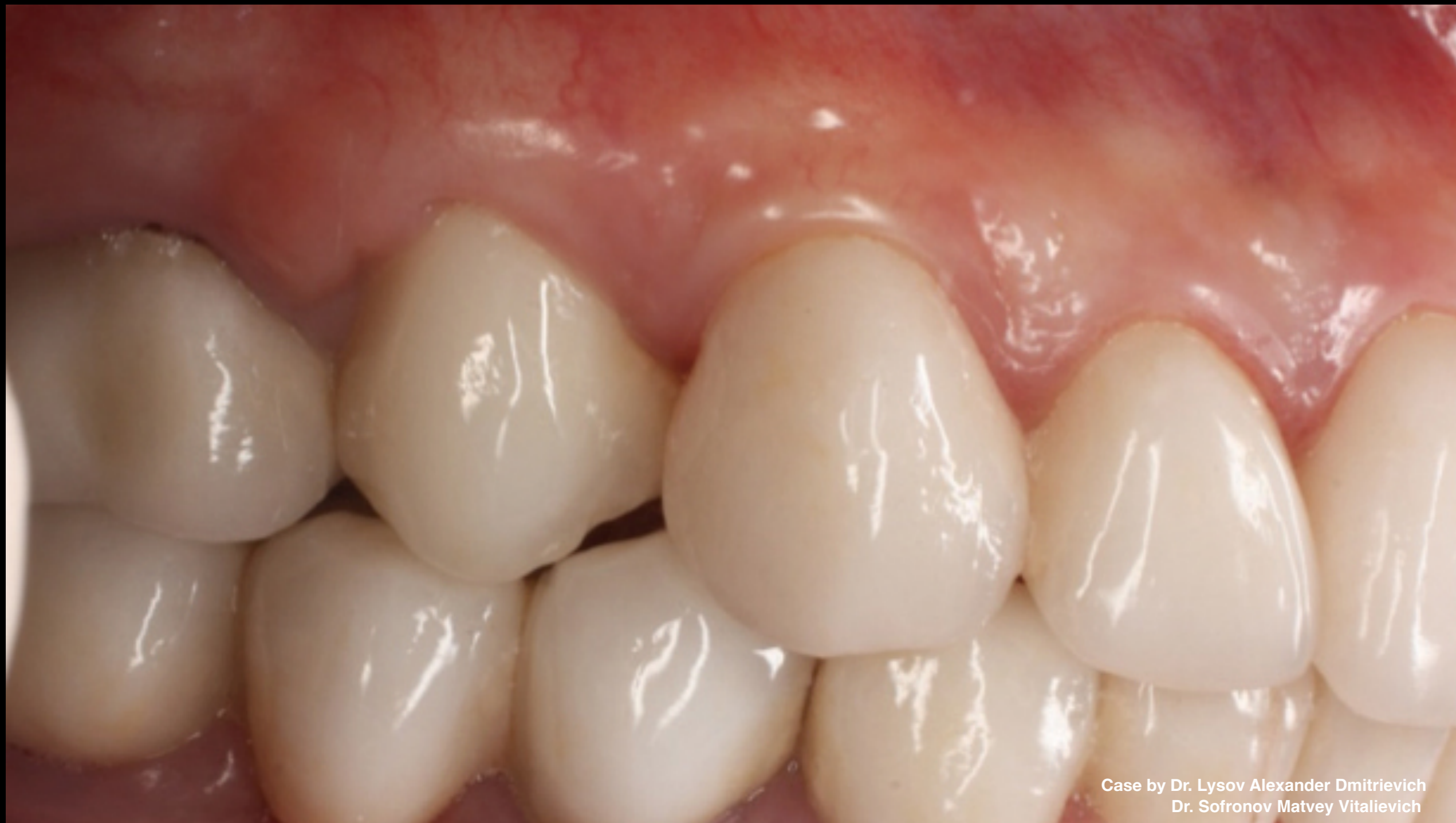Case by Dr. Lysov Alexander Dmitrievich
Dr. Sofronov Matvey Vitalievich

Clinical Case: Installed temporary crown



Case by Dr. Lysov Alexander Dmitrievich
Dr. Sofronov Matvey Vitalievich

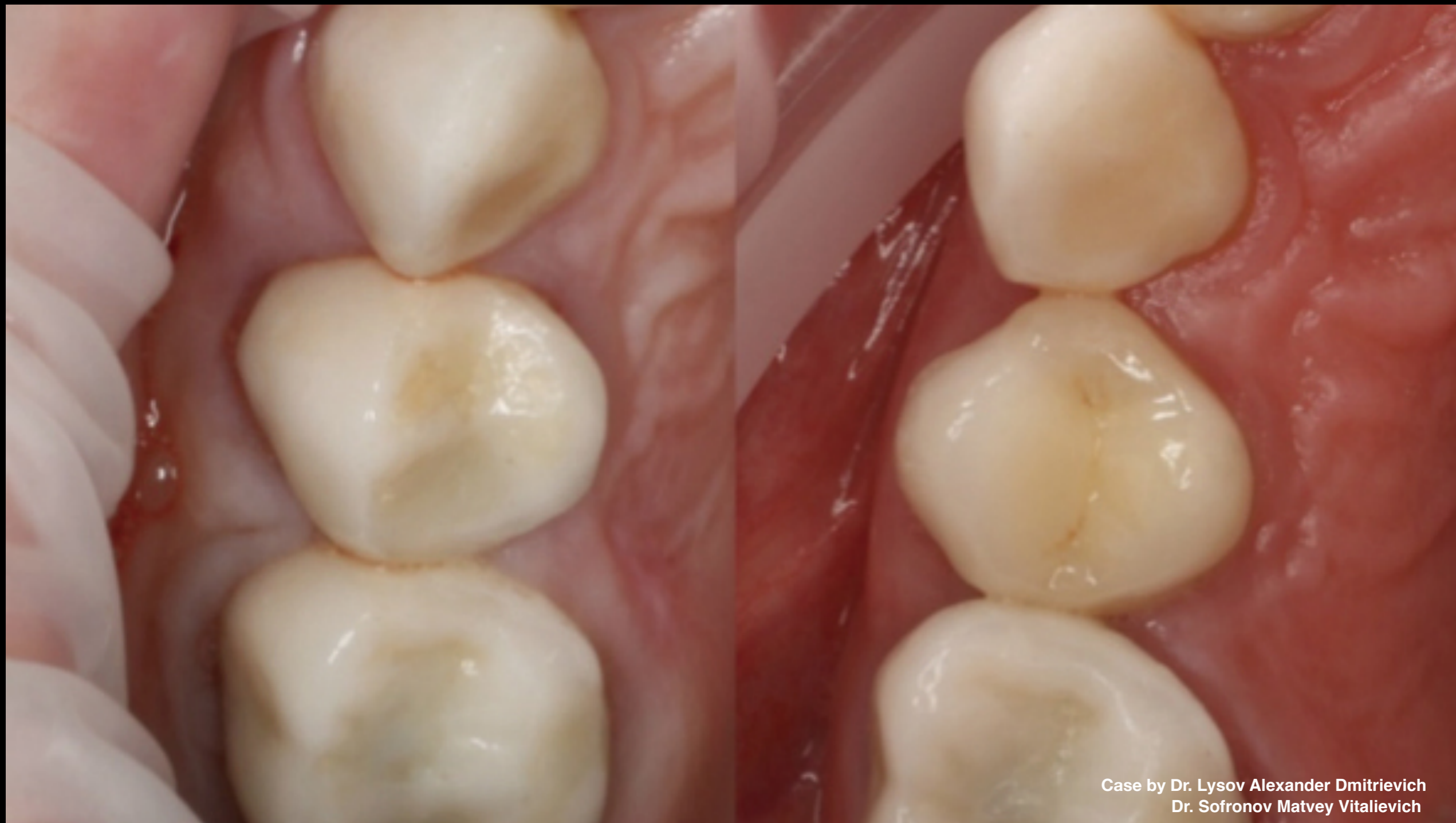Clinical Case: Patient's smile on day of surgery



Case by Dr. Lysov Alexander Dmitrievich
Dr. Sofronov Matvey Vitalievich

Clinical Case: Final results

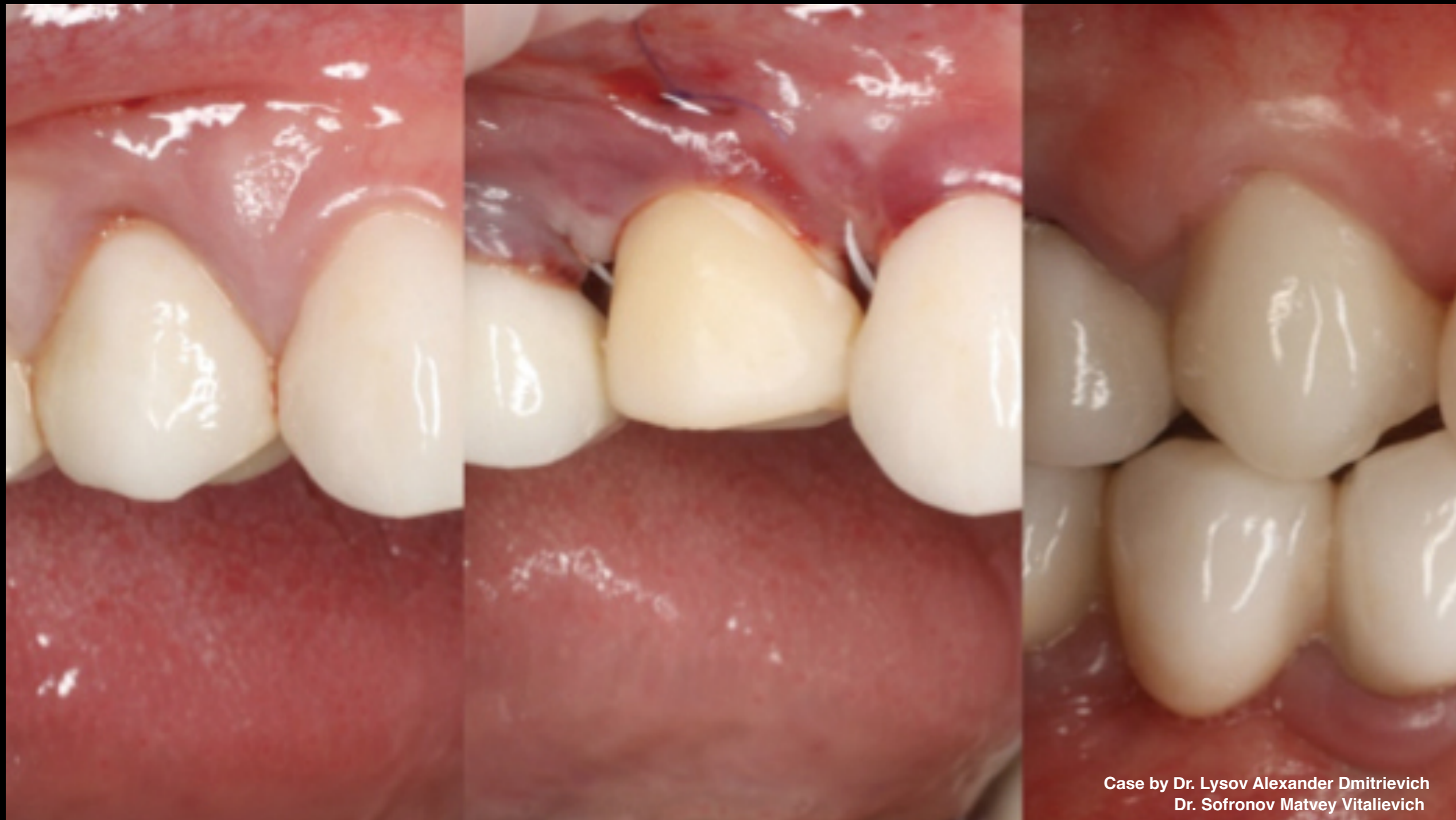3 mths after implant placement, all-ceramic crown with zirconium framework was installed on permanent customized zirconium abutment



Case by Dr. Lysov Alexander Dmitrievich
Dr. Sofronov Matvey Vitalievich

Clinical Case:

- Occlusal view before / after
- Digital Data Save technology & R2GATE surgical guide ensured stable soft tissue in area of dental implant



Clinical Case:

- Vestibular view
- Original situation, temporary crown, final result

